

Arthroscopic rotator cuff repair: Prospective functional outcome and repair integrity at minimum 2-year follow-up

Brian J. Cole, MD, MBA,^a L. Pearce McCarty III, MD,^b Richard W. Kang, MD, MS,^a Winslow Alford, MD,^c Paul B. Lewis, MD, MS,^a and Jennifer K. Hayden, MSN, RN,^a Chicago IL; Minneapolis, MN; Warwick, RI

The purpose of this study was to assess arthroscopic repair of rotator cuff tears at a minimum of 2 years postoperatively with both patient-derived and objective outcome measures, including the use of magnetic resonance imaging (MRI), to evaluate repair status. Evaluated were 49 shoulders in 47 consecutive patients. The American Shoulder and Elbow Surgeons score, Constant and Murley score, Simple Shoulder Test, Rowe score, Visual Analog Pain Scale, and the Medical Outcomes Study Short Form-12 Mental Component Scale all improved significantly ($P < .001$) between the preoperative and final follow-up evaluations. MRI found 22% of repairs had recurrent tears. The presence of a recurrent tear correlated significantly with patient age ($P < .009$) and extension of the tear to the infraspinatus ($P < .009$). Active forward flexion, abduction, external rotation, and strength in forward flexion correlated inversely with the presence of a recurrent tear ($P < .05$). At minimum 2-year follow-up, arthroscopic repair of rotator cuff tears produced significant improvements in both patient-derived and objectively measured variables. (J Shoulder Elbow Surg 2007;xx:xxx.)

With advances in arthroscopic technique and instrumentation, arthroscopic rotator cuff repair has grown in popularity. Although an increasing number of prospective series in the literature report the short-term and intermediate-term results of arthroscopic rotator cuff repair, few offer an objective assessment of strength or evaluation of postoperative repair integrity.^{2,3,4,5,7,11,12,17,21,25} The purpose of the present study was to evaluate the short-term results of arthroscopic repair in patients with full-thickness rotator cuff tears, using both patient-derived functional and objec-

tive outcome measures, including the use of magnetic resonance imaging (MRI) to assess repair integrity.

MATERIALS AND METHODS

Patient selection

Between 2001 and 2004, 138 patients with symptomatic, full-thickness rotator cuff tears were prospectively enrolled in our study, which was approved by the Rush University Medical Center Institutional Review Board. Patients undergoing surgery had failed appropriate conservative treatment. Exclusion criteria included a history of previous shoulder operation, ipsilateral greater tuberosity or clavicle fracture, ongoing litigation, concomitant tears in the labrum, subscapularis or teres minor tear, and adhesive capsulitis. Although 55 shoulders met our inclusion criteria and our minimum follow-up requirement of 2 years, only 49 had complete clinical and radiographic data sets.

Clinical data

Patient data were analyzed using the score of Constant and Murley, the American Shoulder and Elbow Surgeons (ASES) score, the Simple Shoulder Test (SST), the Rowe score, Visual Analog Pain Scale (VAPS), and the Medical Outcomes Study Short Form-12 Physical Component Scale (SF-12 PCS) and Short Form-12 Mental Component Scale (SF-12 MCS).^{8,13,14,20,23,24} Medical metrics included active range of motion in forward flexion, abduction, and external rotation (at 0° abduction), and strength in forward flexion and external rotation (at 0° abduction).

Measurements were obtained preoperatively, at 1 year when possible, and at a minimum of 2 years postoperatively. Strength was measured in kilograms using an Isobex digital strength analyzer (Medical Device Solutions, Burgdorf, Germany). The strength of the unaffected contralateral shoulder was measured as a control. Forward elevation strength testing was performed with an Isobex device with the arm held at 90° of forward elevation and external rotation at the side with the elbow held against the belt line and flexed to 90°.

Patient satisfaction was assessed at the time of final follow-up by asking patients to rate their surgical arm as a percentage of normal and to answer "Yes" or "No" to the question "Would you repeat the surgery and postoperative rehabilitation to achieve the same results?" Measurement of all objective outcome variables and administration of subjective questionnaire evaluations was performed by a trained research assistant not otherwise involved in the care of the patient.

From the ^aDepartment of Orthopaedic Surgery, Rush University Medical Center; ^bSports and Orthopaedic Specialists, and ^cWest Bay Orthopaedics.

Reprint requests: Brian J. Cole, MD, MBA, Rush University Medical Center, 1725 W. Harrison St, Suite 1063, Chicago, IL 60612 (E-mail: bcole@rushortho.com).

Copyright © 2007 by Journal of Shoulder and Elbow Surgery Board of Trustees.

1058-2746/2007/\$32.00

doi:10.1016/j.jse.2006.12.011

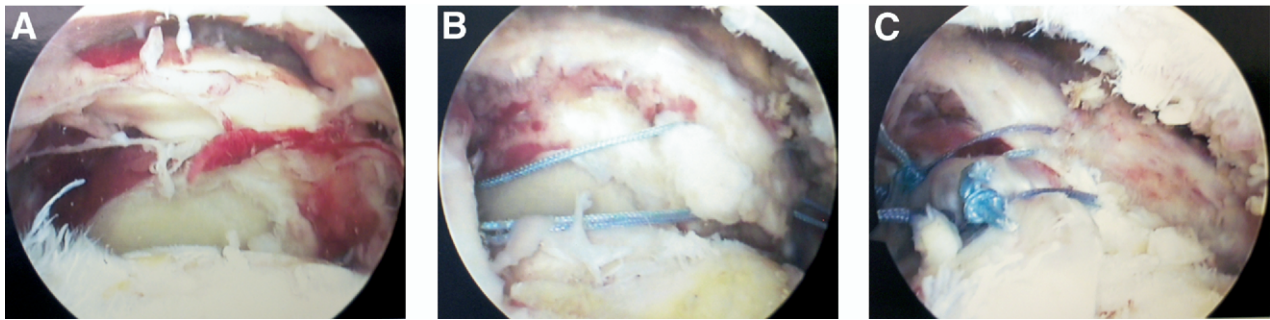


Figure 1 Use of margin convergence technique for large, U-shaped tear. **A**, Large, chronic, U-shaped tear. **B**, Passage of multiple sutures anterior to posterior in preparation for margin convergence. **C**, Margin convergence accomplished with approximation of rotator cuff to greater tuberosity.

Imaging

All patients underwent a series of preoperative plain radiographs, consisting of a true anteroposterior, an axillary, and an outlet view of the affected shoulder. At a minimum of 2 years follow-up, repair integrity was evaluated using nonarthrogram MRI. A 0.3 tesla Hitachi Airis II (Tokyo, Japan) open magnet with a dedicated Hitachi quad coil was used for imaging. Pulse sequences included axial T2 (field of view, 200; repetition time [TR]/time to echo [TE] 4665/125, matrix 192 × 224; thickness, 4 mm; interval, 5 mm), coronal T1 (field of view, 200; TR/TE 400/20; matrix 180 × 256; thickness, 4 mm; interval 5, mm), coronal T2 (field of view, 200; TR/TE 4665/125; matrix, 192 × 224; thickness, 4 mm; interval, 5 mm), coronal IR (field of view, 200; TR/TE 2300/25; matrix 160 × 256; thickness, 4 mm; interval, 5 mm), sagittal T2 (field of view, 200; TR/TE 4506/125; matrix 192 × 224; thickness, 4 mm; interval, 5 mm), and sagittal IR (field of view, 200; TR/TE 2300/25; matrix 160 × 256; thickness, 4 mm; interval, 5 mm). All studies were interpreted by a musculoskeletal-MRI fellowship-trained radiologist with extensive experience in interpretation of shoulder MRI but not otherwise involved in the care of the subjects.

Statistics

Statistical analysis was performed using SPSS 11.5 (SPSS, Inc, Chicago, IL). Descriptive statistics included frequencies, means, standard deviations, and ranges where appropriate. Tests used in this analysis include χ^2 , Mann-Whitney, Wilcoxon signed ranks test, and Kruskal-Wallis. For the analysis of results by patient age, a histogram of each variable was compared with a normal curve before conducting the analysis. The Kruskal-Wallis test for nonparametric data was used to detect differences between all age groups for each outcome variable analyzed. The Mann-Whitney test for nonparametric data was used to conduct a post hoc analysis to determine where significant differences occurred. Results were considered statistically significant at $P < .05$.

Surgical technique

A single-row suture anchor technique was used as described previously.^{8,24} Tear sizes were classified intraoper-

atively according to the convention described by DeOrio and Cofield.¹⁰ Tear patterns were classified by the convention described by Burkhart et al.^{6,7} Tear patterns that fell into the crescent-shaped category were repaired using a single-row suture anchor configuration with 2 sutures per eyelet. Tear patterns that were L-shaped or U-shaped were mobilized and addressed first using a margin convergence technique (Figure 1). The single-row suture anchor technique was then used to complete the repair as described.

Concomitant biceps tendon procedures included tenotomy in 4 patients and subpectoral tenodesis in 19 patients. Decision for tenotomy versus tenodesis was determined by a preoperative discussion with the patient, the patient's concern about the potential for cosmetic difference between the operative and nonoperative limb, and the age and activity level of the patient.

Postoperative management

All patients followed the same postoperative rehabilitation protocol. Extremities were immobilized in a sling for 4 weeks, removed only for hygiene and supervised physical therapy. During the initial 4 weeks, therapy consisted of gentle pendulum exercises. Passive range of motion under the direction of a physical therapist was also permitted to tolerance in forward flexion, with internal rotation limited to 40° at 90° of forward elevation. The patient's elbow was maintained anterior to the midaxillary line during all exercises.

After 4 weeks, patients were transitioned to gentle active assisted exercises without resistance, and at 6 weeks, deltoid and biceps strengthening was initiated. From 9 to 12 weeks, scapular stabilization exercises continued, and posterior capsule stretching was emphasized. At 4 to 6 months, patients focused on sports-specific activities and returned to sports participation or work, as tolerated, depending on specifics of the cuff tear and the selected activity. Patients who underwent concomitant biceps tenodesis were instructed to avoid active elbow flexion during the initial 4 weeks postoperatively.

RESULTS

We evaluated 49 shoulders in 47 patients (28 men, 19 women). Their average age at the time of

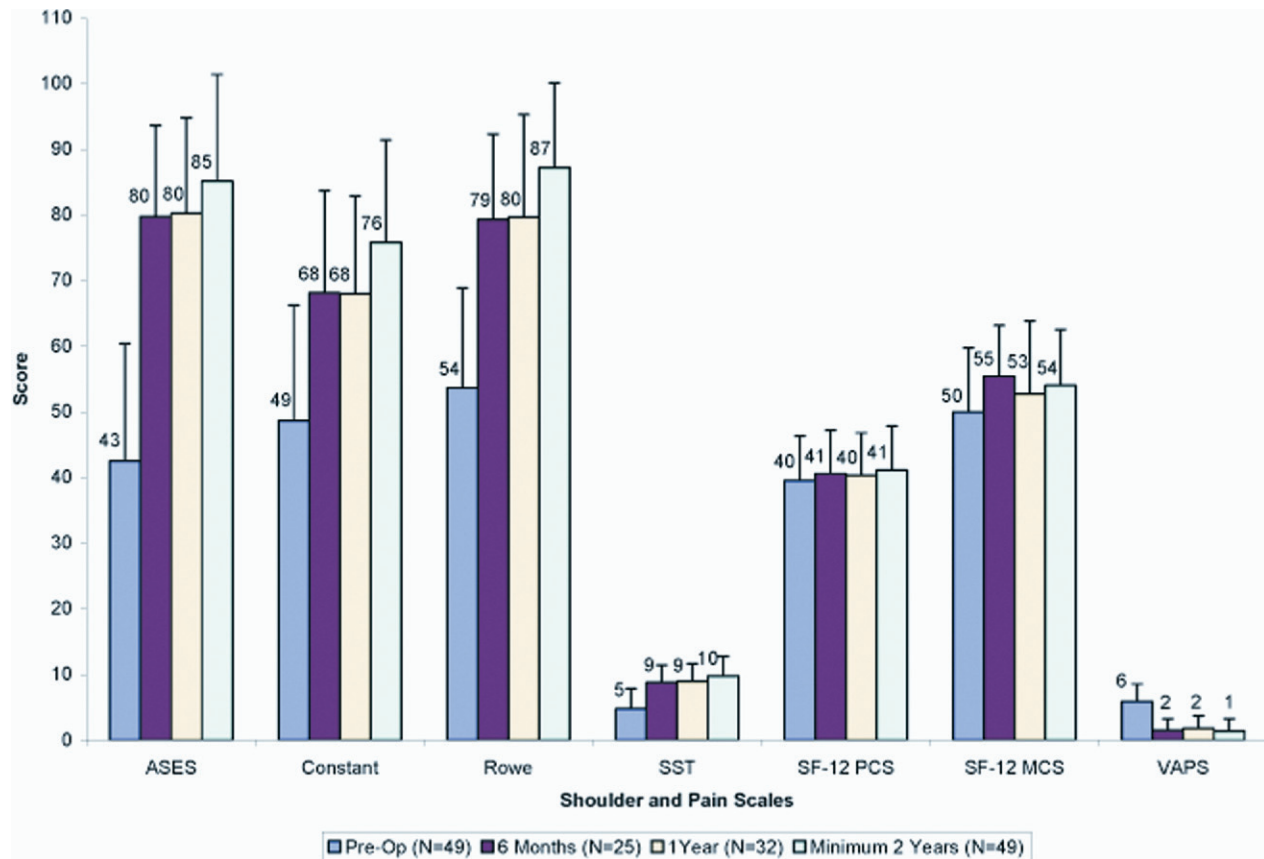


Figure 2 Overall subjective scores are shown with standard deviation bars. ASES, American Shoulder and Elbow Surgeons; SST, Simple Shoulder Test; SF-12 PCS, Short Form-12 Physical Component Score; SF-12 MCS, Short Form-12 Mental Component Score.

surgery was 57 years (range, 34-80 years). The average interval from time of injury to surgery was 17 months (range, 2-197 months). The affected shoulder was on the dominant side in 35 (71%) and on the nondominant side in 14 (29%). Twenty-two (47%) patients were on Workers Compensation. The average duration of clinical follow-up was 32 months (range, 24-45 months).

Operative findings

Nine small (18%), 29 medium (60%), 2 large (4%), and 9 massive tears (18%) were identified. There were 12 U-shaped tears (24%), 7 L-shaped tears (14%), and 30 crescent-shaped tears (62%). The involved musculotendinous units included the supraspinatus only for 41 shoulders (84%) and the supraspinatus and infraspinatus for 8 (16%).

Patient-derived functional scores

A summary of the overall functional scores according to the ASES, Constant, Rowe, SST, VAPS, SF-12 PCS, and SF-12 MCS systems is shown in Figure 2

Table 1 Overall subjective scores comparing preoperative status versus status at 1 and 2 years postoperatively

Instrument	Pre-op (n = 49)	1 year (n = 32)	P	Minimum 2 years (n = 49)	P
ASES	43	80	<.0001	85	.0001
Constant	49	68	<.0001	76	.0001
Rowe	54	80	.0001	87	.0001
SST	4.8	8.9	.0001	9.8	.0001
SF-12 PCS	40	40	.569	41	.094
SF-12 MCS	50	53	.158	54	.023
VAPS	5.9	1.8	<.0001	1.4	<.0001

ASES, American Shoulder and Elbow Surgeons; SST, Simple Shoulder Test; SF-12 PCS, Short Form-12 Physical Component Scale; SF-12 MCS, Short Form-12 Mental Component Scale; VAPS, Visual Analog Scale.

and Table 1. Significant improvement occurred in all scores except for the SF-12 PCS. For the 32 patients for whom complete clinical follow-up was available at both 1 and 2 years postoperatively, significant improvement was observed in Constant ($P < .001$),

Table II Overall subjective scores comparing status at 1-year and minimum 2-year follow-up periods for patients with complete follow-up

Instrument	1 year (n = 32)	Minimum 2 years (n = 32)	P
ASES	80	87	.056
Constant	68	78	<.0001
Rowe	80	89	.005
SST	8.9	10.3	.006
SF-12 PCS	40	41	.493
SF-12 MCS	53	55	.505
VAPS	1.8	1.4	.328

ASES, American Shoulder and Elbow Surgeons; SST, Simple Shoulder Test; SF-12 PCS, Short Form-12 Physical Component Scale; SF-12 MCS, Short Form-12 Mental Component Scale; VAPS, Visual Analog Scale.

Rowe ($P = .005$), and SST ($P = .006$) scores between years 1 and 2 (Table II).

Pain

When considered in isolation, 43 cases had a decrease, 2 had no change, and 4 had an increase in their VAPS between the preoperative and final follow-up period. Two of these 4 patients had retears.

Strength and range of motion

A significant difference was seen between the preoperative and postoperative periods for forward flexion and external rotation strength. Forward flexion strength increased from a mean of 2.9 kg preoperatively to 4.4 kg at 1 year ($P < .025$) and 5.3 kg at minimum 2 years ($P < .001$). External rotation strength also increased significantly from a mean of 3.9 kg preoperatively to 5.9 kg at 1 year ($P < .003$) and 7.1 kg at minimum of 2 years ($P < .001$).

Significant increases in all range of motion assessments were seen between preoperative and final follow-up periods (Table III). No significant differences were noted between affected and unaffected shoulders at the final follow-up period for forward flexion ($P = .753$), abduction ($P = .959$), and external rotation ($P = .123$).

Patient satisfaction

In 47 cases (96%), the patients said that they would do the surgery again. Neither intraoperative tear size ($P = .697$) nor concomitant biceps procedure ($P = .250$) was a significant determinant of whether the patients wanted to have the surgery again. Patients also subjectively noted their affected shoulders as 87% of normal for strength and function at final the follow-up.

Recurrent tears

MRI identified recurrent tears in 22% of shoulders (11/49). When analyzed by tear size at the time of surgery, recurrent tears were identified in 16% of small and medium tears and in 46% of large and massive tears ($P < .04$).⁹ Although no significant differences were found in any of the functional scores measured between intact and retear groups (regardless of preoperative tear size), objective measures did differ (Table IV). Compared with the original tear size, the recurrent tears were smaller in 4 cases (36%), the same size in 3 (28%), and larger in 4 (36%).

Age of 70 years or older ($P < .009$) and preoperative extension of the tear into the infraspinatus ($P < .009$) were significantly associated with presence of a recurrent tear. Factors not significantly associated with recurrent tears include concomitant biceps procedures, number of suture anchors used, time interval from injury to surgery, gender, dominant or nondominant side being affected, Workers Compensation status, or tear pattern ($P > .05$).

Complications

There were no infections, neurovascular injuries, instances of postoperative shoulder stiffness, or other complications requiring intervention.

Results by patient age

The patient population was separated into the following age groups by decade: ≤ 49 (12 shoulders), 50 to 59 years (19 shoulders), 60 to 69 years (10 shoulders), and ≥ 70 years (8 shoulders). No significant differences were found among any of the groups in the preoperative period with respect to any of the outcome variables measured.

At final follow-up, however, significant differences were found between the group aged ≤ 49 years and the group aged 60 to 69 with respect to VAPS ($P = .036$) and external rotation power ($P = .014$). Differences were also significant between the group aged 50 to 59 and the 60 to 69 with respect to VAPS ($P = .037$). There were no differences between the group aged ≤ 49 and the group aged 50 to 59 among any of the outcome variables measured.

The proportion of retears increased with age. The retear rate was 8.3% (1/12) for the group aged ≤ 49 years, 10.5% (2/19) for the group 50 to 59 years, 30.0% (3/10) for the group 60 to 69 years, and 62.5% (5/8) for the group ≥ 70 years. The Spearman correlation for retear by age group was $\rho = 0.407$ ($P = .004$). There were no significant differences between the affected and unaffected sides for all strength and range of motion assessments for the groups aged ≤ 49 , 50 to 59, and 60 to 69. The

Table III Range-of-motion assessments

Measure	Range of motion (degrees)						
	Pre-op	6 months	P*	1 year	P*	Minimum 2 years	P*
Flexion	136	159	.150	162†	.014	172†	<.0001†
Abduction	121	143	.091	153†	.006†	165†	<.0001†
Rotation	57	62	.197	66	.668	76†	<.0001†

*P values represent level of significance between pre-op and follow-up.

†Statistically significant.

Table IV Significant differences between return and intact repair groups

Variable	Return	Intact	P
Age (years)	64	55	.009
Range of motion (degrees)			
Forward flexion	164	174	.017
Abduction	153	168	.037
External rotation	66	79	.041
Forward flexion strength (kg)	3.9	5.8	.050
Infraspinatus involvement on			
DOS	5 (62.5%)	3 (37.4%)	.009
VAPS	1.5	1.4	.677

DOS, Date of surgery; VAPS, Visual Analog Pain Scale.

group aged ≥ 70 years had significant differences for forward flexion range of motion, external rotation range of motion, and forward flexion strength; however, the differences for abduction range of motion and external rotation strength were not significant.

Workers compensation

Twenty-two cases (47%) involved Workers Compensation claims. Significant preoperative differences were noted between the Workers Compensation and non-Workers Compensation groups (Table V). Generally, the Workers Compensation group tended to include younger patients, more men, smaller tear sizes, and higher measured levels of strength than the non-Workers Compensation group. Workers Compensation status did not affect patient satisfaction, pain assessment, functional outcome scores, range of motion, retear rate, or retear size ($P > .05$).

DISCUSSION

The findings reported in this study demonstrate that at short-term follow-up, arthroscopic rotator cuff repair results in significant pain relief and improvement in active range of motion, strength, and function. When viewed with respect to existing, peer-reviewed literature, the results reported in this series at time of final follow-up compare favorably with those reported in other isolated series of all arthroscopic rotator cuff

Table V Significant differences between groups with and without Workers Compensation

Variable	WC		P
	(n = 22)	Non-WC (n = 25)	
Age (years)	52	61	.001
Males	78% (17)	25% (11)	.011
Affected side = dominant side	87% (19)	58% (15)	.024
Small-medium original tear side	87% (19)	69% (17)	.030
Forward flexion strength (kg) at pre-op	3.9	2.3	.011
Forward flexion strength (kg) at 2 years	6.7	4.2	.004
External rotation strength (kg) at pre-op	5.4	3/0	.006
External rotation strength (kg) at 2 years	8.3	6.7	.027
Infraspinatus involvement on DOS	0% (0)	31% (8)	.004

WC, Workers Compensation; DOS, day of surgery.

repairs with respect to ASES, SST, Constant and Murley, VAPS, patient satisfaction, objectively measured strength, and active range of motion.^{3-5,12,17}

Of interest was significant improvement in Constant, Rowe, and SST scores from year 1 to year 2 in a subset of patients for whom complete data were available at both 1-year follow-up and final follow-up. Galatz et al¹¹ have published the only other study, of which we are aware, that compares results at 1 and 2 years after arthroscopic rotator cuff repair. In their series of 18 patients with either large or massive tears, the authors reported a mean ASES score of 84.6 at 1 year and 79.9 at the final follow-up at 2 years, demonstrating a decrease rather than an increase in patient-reported functional status. Most of the tears in our series were small and medium sized, which likely explains the difference between their results and those reported in our study.

Owing to the short-term follow-up of this study, we are neither able to determine the time at which postoperative functional gains plateau after arthroscopic rotator cuff repair nor the ultimate durability of the gains observed. A more accurate estimation of the time needed to achieve maximal improvement will require longer-term follow-up. Nevertheless, this information may serve useful when counseling patients about postoperative expectations and the timeline of postoperative gains.

Multiple imaging modalities have been reported for the evaluation of index and recurrent tears of the rotator cuff, including conventional arthrography, computed tomography arthrography, ultrasound imaging, and MRI.^{1,10,15,16,18,19,22} MRI has a reported sensitivity of 84% to 91% and specificity of 25% to 91% in the detection of a full-thickness tear of the rotator cuff after repair.^{10,16,19} Currently, 4 arthroscopic studies provide data on postoperative repair status, with retear rates of 27% to 94%.^{5,11,21,25} Among all-arthroscopic series, our retear rate is comparable with that recently reported by Boileau et al⁵ (29%), and with that reported by Sugaya et al²¹ for single-row repair (13% for small and medium tears and 44% for large and massive tears), higher than that reported by Sugaya et al for dual-row repair (0% for small and medium tears and 29% for large and massive tears), and differs markedly from that reported by Galatz et al¹¹ for large and massive tears (94%).

In our series, patients aged 70 years and older had a higher proportion of retears than those in younger age groups (5/8 [62.5%]). Boileau et al⁵ also observed a lower healing rate in older patients in their arthroscopic series, with only 43% of patients age 65 years and older having intact repairs at time of radiographic follow-up.

We did not find significant differences between the intact and retear repair groups for any of the patient-derived functional outcome instruments measured. We recognize this finding could be due to sample size and plan to reexamine this finding in a future study reporting on intermediate-term results.

A sizeable proportion of the patient population (47%) in our series involved Workers Compensation claims. Stratification of patients into those involving and those not involving Workers Compensation claims revealed no differences in any of the patient-reported, functional outcomes measured but did reveal significant differences in both forward flexion strength and external rotation strength at time of final follow-up. Of interest was that the Workers Compensation group tested at a higher strength in both cases than the non-Workers Compensation group. We suspect the explanation for this observed difference rests in the fact that the Workers Compensation group had a higher percentage of small-sized and medium-sized tears, as well as being a significantly younger and more predominantly male population than the non-Workers Compensation group. Furthermore, no patient in the Workers Compensation group had preoperative tear extension into the infraspinatus, the latter being a factor observed to have a significant association with lower values of objectively measured outcome variables.

Limitations in this study include, most notably, the fact that only 32 of 49 patients had follow-up data at

1 year. We recognize that our finding of significant improvement in multiple areas from year 1 to year 2 might have been significantly different had a complete data set been available for analysis. Furthermore, we recognize that our inability to detect significant differences between intact and retear groups with respect to Constant, Rowe, ASES, SST, VAPS, SF-12 MCS, and SF-12 PCS scores may have resulted from limited power and sample size and plan to investigate these findings in future studies.

After a short-term follow-up of arthroscopic rotator cuff repairs, we observed significant, durable improvement in virtually all outcomes measured. Our observed overall retear rate of 22% compares favorably with other studies reported in the literature, regardless of repair technique or imaging modality used. Finally, we observed significant differences in age, active range of motion, and strength when comparing intact and retear repair groups. In the hands of an experienced shoulder arthroscopist, arthroscopic repair produces both excellent patient-derived and objective results.

We sincerely thank Dr Anthony M. Zelazny for his expertise and time in reading the MRIs.

REFERENCES

- Balich S, Sheley RB, TR, Sauser D, Quinn S. MR imaging of the rotator cuff tendon: interobserver agreement and analysis of interpretive errors. *Radiology* 1997;204:191-4.
- Bennett WF. Arthroscopic repair of anterosuperior (supraspinatus/subscapularis) rotator cuff tears: a prospective cohort with 2- to 4-year follow-up. Classification of biceps subluxation/instability. *Arthroscopy* 2003;19:21-33.
- Bennett WF. Arthroscopic repair of full-thickness supraspinatus tears (small-to-medium): A prospective study with 2- to 4-year follow-up. *Arthroscopy* 2003;19:249-56.
- Bennett WF. Arthroscopic repair of massive rotator cuff tears: a prospective cohort with 2- to 4-year follow-up. *Arthroscopy* 2003;19:380-90.
- Boileau P, Brassart N, Watkinson DJ, Carles M, Hatzidakis AM, Krishnan SG. Arthroscopic repair of full-thickness tears of the supraspinatus: Does the tendon really heal? *J Bone Joint Surg Am* 2005;87:1229-40.
- Burkhart SS, Athanasiou KA, Wirth MA. Margin convergence: a method of reducing strain in massive rotator cuff tears. *Arthroscopy* 1996;12:335-8.
- Burkhart SS, Danaceau SM, Pearce CE, Jr. Arthroscopic rotator cuff repair: Analysis of results by tear size and by repair technique-margin convergence versus direct tendon-to-bone repair. *Arthroscopy* 2001;17:905-12.
- Constant CR, Murley AH. A clinical method of functional assessment of the shoulder. *Clin Orthop Relat Res* 1987;160-4.
- DeOrto JK, Cofield RH. Results of a second attempt at surgical repair of a failed initial rotator-cuff repair. *J Bone Joint Surg Am* 1984;66:563-7.
- Gaenslen E, Satterlee C, Hinson G. Magnetic resonance imaging for evaluation of failed repairs of the rotator cuff. Relationship to operative finding. *J Bone Joint Surg Am* 1996;78:1391-6.
- Galatz LM, Ball CM, Teefey SA, Middleton WD, Yamaguchi K. The outcome and repair integrity of completely arthroscopically repaired large and massive rotator cuff tears. *J Bone Joint Surg Am* 2004;86:219-24.

12. Gartsman GM, Khan M, Hammerman SM. Arthroscopic repair of full-thickness tears of the rotator cuff. *J Bone Joint Surg Am* 1998;80:832-40.
13. King GJ, Richards RR, Zuckerman JD, Blasier R, Dillman C, Friedman RJ, et al. A standardized method for assessment of elbow function. Research Committee, American Shoulder and Elbow Surgeons. *J Shoulder Elbow Surg* 1999;8:351-4.
14. Lippitt SB, Harryman DT 2nd, Matsen FA 3rd. A practical tool for evaluating function: the Simple Shoulder Test. In: Matsen FA, 3rd, Fu FH, Hawkins RJ, editors. *The shoulder: a balance of mobility and stability*. Rosemont, IL: American Academy of Orthopaedic Surgeons; 1993. p. 501-18.
15. Martin-Hervas C, Romero J, Navas-Acien A, Reboiras J, Munuera L. Ultrasonographic and magnetic resonance images of rotator cuff lesions compared with arthroscopy or open surgery findings. *J Shoulder Elbow Surg* 2001;10:410-5.
16. Motamedi A, Urrea L, Hancock R, Hawkins R, Ho C. Accuracy of magnetic resonance imaging in determining the presence and size of recurrent rotator cuff tears. *J Shoulder Elbow Surg* 2002;11:6-10.
17. Murray TF, Jr., Lajtai G, Mileski RM, Snyder SJ. Arthroscopic repair of medium to large full-thickness rotator cuff tears: outcome at 2- to 6-year follow-up. *J Shoulder Elbow Surg* 2002;11:19-24.
18. Needell S, Zlatkin M. Comparison of fat-saturation fast spin echo versus conventional spin-echo MRI in the detection of rotator cuff pathology. *J Magn Reson Imaging* 1997;7:674-7.
19. Owen R, Iannotti JP, Kneeland J, Dalinka M, Deren J, Oleaga L. Shoulder after surgery: MR imaging with surgical validation. *Radiology* 1993;186:443-7.
20. Rowe CR, Patel D, Southmayd WW. The Bankart procedure. *J Bone Joint Surg Am* 1978;60:1-16.
21. Sugaya H, Maeda K, Matsuki K, Moriishi J. Functional and structural outcome after arthroscopic full-thickness rotator cuff repair: single-row versus dual-row fixation. *Arthroscopy* 2005;21:1307-16.
22. Teefey SA, Rubin DA, Middleton WD, Hildebolt CF, Leibold RA, Yamaguchi K. Detection and quantification of rotator cuff tears. Comparison of ultrasonographic, magnetic resonance imaging, and arthroscopic findings in seventy-one consecutive cases. *J Bone Joint Surg Am* 2004;86:708-16.
23. Ware JE, Sherbourne CD. The MOS 36-item short-form health survey (SF-36). I. Conceptual framework and item selection. *Med Care* 1992;30:473-83.
24. Ware JE. Standards for validating health measures: definition and content. *J Chronic Dis* 1987;40:473-80.
25. Wilson F, Hinov V, Adams G. Arthroscopic repair of full-thickness tears of the rotator cuff: 2- to 14-year follow-up. *Arthroscopy* 2002;18:136-44.