

Cartilage Restoration, Part 2

Techniques, Outcomes, and Future Directions

J. Winslow Alford,* MD, and Brian J. Cole,^{††} MD, MBA

From *Shoulder and Sports Medicine Division, West Bay Orthopedics, Warwick, Rhode Island, and the [†]Department of Orthopedics & Anatomy and Cell Biology, Rush Cartilage Restoration Center, Rush University, Chicago, Illinois

In part 1 of this 2-part Current Concepts article, the authors reviewed the basic science of normal articular and meniscal cartilage and its response to injury. They reviewed the historical perspectives and basic science behind these various methods and presented a rationale for patient evaluation, treatment selection, and timing. In part 2, the authors review the specific indications for the treatment of chondral injuries and describe the techniques and outcomes of the various treatment options, including palliative, reparative, and restorative procedures. In addition, they will examine specific complex clinical scenarios emphasizing treatment options of comorbid conditions including ligament instability, meniscal deficiency, and malalignment. A limited review of the application of these techniques in joints other than the knee will also be presented. A conceptual algorithm is developed to assist in clinical decision making.

Keywords: cartilage restoration; techniques; outcomes; microfracture; autologous chondrocyte implantation; allograft; osteochondral autograft transfer; mosaicplasty; comorbidities

In part 1 of this 2-part Current Concepts article, we reviewed the basic science of normal articular and meniscal cartilage and its response to injury. We reviewed the historical perspectives and basic science of various cartilage restoration methods and presented a rationale for patient evaluation, treatment selection, and timing. In part 2, we review the specific indications for the treatment of chondral injuries and describe the techniques and outcomes of the various treatment options. In addition, we examine specific complex clinical scenarios emphasizing comorbid conditions including ligament instability, meniscal deficiency, and malalignment. A limited review of the application of these techniques in joints other than the knee is also presented. A conceptual algorithm is developed to assist in clinical decision making.

After each technique description, a brief review of outcomes is presented. In these outcomes, there is a preponderance of subjective data related to patients' reports of decreased symptoms and increased function. Objective data, including direct arthroscopic visualization, MRI, and biopsies of the treated lesions, are included where available.

[†]Address correspondence to Brian J. Cole, MD, MBA, 1725 West Harrison Street, Suite 1063, Chicago, IL 60612 (e-mail: bcole@rushortho.com).

No potential conflict of interest declared.

TECHNIQUES

Fixation of Osteochondral Fractures/ Osteochondritis Dissecans Lesions

Symptomatic focal chondral lesions are often associated with a specific traumatic event resulting in a true osteochondral fracture. Decision making regarding fixation of osteochondral fragments will depend on the condition and quantity of articular cartilage, the size of the associated subchondral bone, as well as the shape, thickness, viability (extent of necrosis and measure of chronicity), and site of the lesion in the knee. We attempt repair of a long-standing osteochondritis dissecans (OCD) lesion only if it becomes truly symptomatic or becomes traumatically displaced.

In cases involving chronic symptomatic fragments, fibrous tissue is often interposed under the fragment, which can impede anatomical reduction and healing. If the fragment is severely comminuted, avascular, deformed, or otherwise irreparable, it may require removal. If at all possible, however, articular surface fractures or symptomatic OCD fragments should be reduced, stabilized, and bone grafted if required.^{87,92,97} Osteochondritis dissecans has long been recognized to occur in the capitellum,⁶⁷ wrist,²⁷ distal tibia,⁷ talus,⁴ femoral head,⁷¹ and patella⁸⁵ but is most commonly found on the femoral condyle,² and therefore we will focus on the surgical techniques of fixation on the femoral condyle.

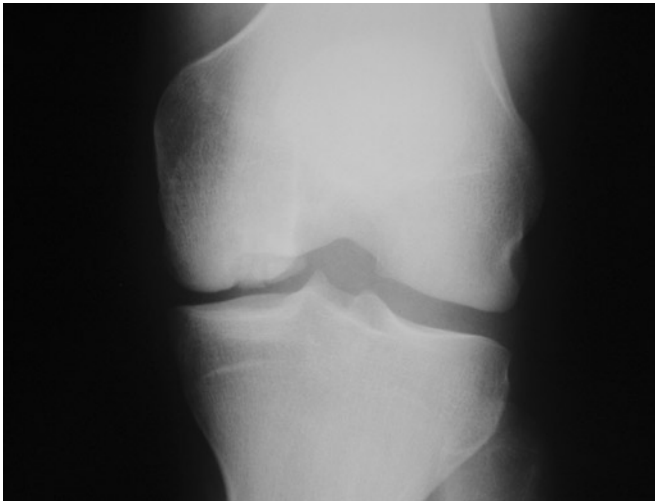


Figure 1. An AP radiograph demonstrating osteochondritis dissecans lesion with subchondral bone involvement on the lateral aspect of the medial femoral condyle.

First, nonviable or necrotic debris under the fragment is removed with a shaver, rasp, or curette. Fixation is advised for symptomatic unstable OCD fragments with adequate subchondral bone as seen on plain radiographs (Figure 1) that are detached or mobile when probed or that have evidence on T2-weighted images of synovial fluid dissection through or behind the base of the lesion (Figures 2 A and B). For lesions located at readily accessible surfaces of the femoral condyle, arthroscopic reduction and fixation are often possible. Less common patella and tibial plateau lesions are more challenging locations; an arthrotomy is usually required to ensure adequate exposure, reduction, and secure fixation. For arthroscopic fixation, accessory portals should be used if needed to ensure that the fixation device is inserted perpendicular to the fracture plane. Often, 2 or more points of fixation are required to provide rotational stability. Drilling an OCD lesion is thought to create a biologic stimulus for healing. To promote the local biologic response, a 0.062-inch-diameter smooth Kirschner wire may be used with either a retrograde or antegrade technique.¹ Retrograde drilling necessitates care to avoid the open physis, and antegrade requires care to avoid penetrating normal or intact articular cartilage.³ Alternatively, a microfracture awl is used to violate the subchondral bone and to induce bleeding and egress of marrow elements. Cancellous bone graft may be obtained from the Gerdy tubercle or the intercondylar femoral notch by using osteochondral autograft harvest devices. Postoperative care includes nonweightbearing for up to 6 to 8 weeks and early range of motion, including continuous passive motion (CPM), if available to the patient.

For fixation, we recommend headless metallic cannulated screws with a differential thread pitch, which provide a lag effect, compressing the fragment into its native bed. These screws are easily countersunk below the articular surface, and although they often provide optimal fixation, they may require staged arthroscopic removal. If metallic fix-

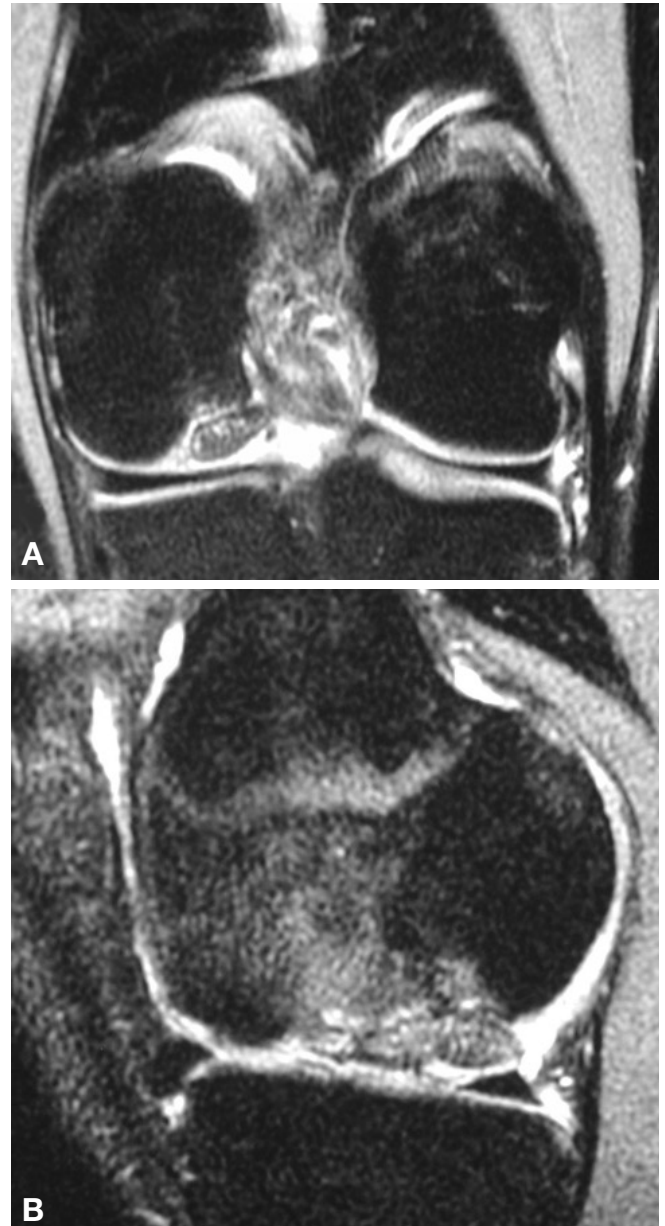

Figure 2. An MRI of osteochondritis dissecans on the lateral aspect of medial femoral condyle, (A) coronal view and (B) sagittal view, demonstrating fluid dissection behind the base of the lesion.

tion is used, then the hardware is removed after clinical and radiographic signs of healing at up to 3 months postoperatively. After this technique, success rates of 80% to 90% have been reported, with poorer results in lateral femoral condyle lesions.^{2,23,97} Metallic staple fixation is not recommended, as these staples are associated with low (50%) healing rates and a significant rate (30%) of staple breakage.⁵⁴ Bioabsorbable devices are available for smaller lesions or if the lesion consists mostly of cartilage with scant subchondral bone available for fixation. Advantages of bioabsorbable fixation devices are a lower profile with

smaller bore perforation of the articular surface and unlikely need for staged removal of hardware. The disadvantages of these devices include potentially inferior fixation strength, less interfragmentary compression compared to metallic devices, higher implant cost, and the potential for osteolysis in the case of rapid polymer breakdown causing localized lactic acid overload.⁹⁴ Series with small numbers and short follow-up cautiously recommend bioresorbable fixation as first-line treatment of nondisplaced fragments, with metallic fixation reserved for primary failures or more unstable fragments in the femoral condyles.⁹⁶ Successful biologic fixation of femoral condyle OCD with autologous osteochondral plugs has also been reported.^{9,68}

Reports of OCD fixation in the patella,⁸⁰ including techniques for retrograde fixation of OCD lesions of the patella using fluoroscopic guidance, are present in the literature, but outcomes of such an uncommon entity remain unclear.⁸¹ Series with small numbers demonstrate encouraging results after arthroscopic fixation of OCD of the capitellum.^{18,58,76}

There are currently no randomized clinical trials examining the treatment of OCD of the talar dome. One recent comprehensive review by Verhagen et al identified 39 studies comparing the options of nonoperative treatment; excision; excision and curettage; excision, curettage and drilling; bone graft after excision and curettage; osteochondral transplantation; or fixation and retrograde drilling. In that review, excision, curettage, and drilling had the best subjective outcome of 86% good to excellent at a minimum of 2 years, but a definitive conclusion could not be drawn from the data available.⁹³ Finally, OCD of the capitellum has also been reported with fixation leading to successful symptom resolution.⁴⁸

Marrow-Stimulating Techniques

Abrasion Arthroplasty. Abrasion arthroplasty is traditionally performed arthroscopically with a shaver or bur, with recommendations to remove 1 to 2 mm of exposed sclerotic bone down to the vasculature of the subchondral plate.¹⁰ This results in a fibrin clot that later develops into fibrocartilage. Although abrasion arthroplasty is based on sound biologic principles, results comparing simple debridement with the addition of abrasion arthroplasty indicate that for both groups, roughly half of the patients improved, but 33% of the abrasion arthroplasty group reported a worse Hospital for Special Surgery (HSS) knee score than before surgery.¹⁰ Abrasion arthroplasty appears to be technique sensitive, and minimizing the amount of subchondral bone destruction remains challenging.

Microfracture. The microfracture technique uses the same sound biologic principles as the abrasion arthroplasty without systematic bone removal. Arthroscopically, angled awls are used to perforate the subchondral bone of focal articular cartilage surface lesions.^{11,35,36,90} By creating perforations without power drilling, the potential risk for

thermal necrosis is eliminated, and a more controlled and precise subchondral bone perforation depth and location can be obtained. The perforations should access the underlying cancellous bone, resulting in release of blood and mesenchymal cells, leading to reparative tissue formation. Under protected loading conditions and CPM, the cells in the resulting "superclot" proliferate and differentiate into a fibrous or fibrocartilage mosaic repair tissue.²⁸

Ideal indications for microfracture treatment include focal grade III or IV articular surface lesions without bone loss that are surrounded by normal articular cartilage in a young patient. Contraindications include significant subchondral bone loss, mechanical axis malalignment, bipolar lesions, or a high risk of noncompliance with postoperative rehabilitation protocols. A disadvantage of this technique is that, at best, repair tissue will be composed of predominantly type I collagen-rich fibrocartilage, which does not resist compression and shear loads as predictably as hyaline cartilage does and is likely less durable over time.

The first step in this procedure is critical to its success and involves creating precise perpendicular edges of the lesion at the transition zone adjacent to the healthy articular cartilage. Thus, a "well-shouldered" lesion will improve the local mechanical environment by reducing shear and compression on the lesion, thereby allowing the formation of fibrocartilage. All unstable cartilage should be removed. Animal studies suggest that removing the calcified cartilage with a curette greatly enhances the percentage and quality of defect fill.²⁹ A surgical awl is then used to create holes placed 2 to 3 mm apart beginning first at the periphery of the lesion. Great care should be taken to prevent confluence of the holes, as this will cause unstable bone fragments that may break free from between the holes. When fat droplets can be seen coming from the marrow cavity, the approximate depth (2-4 mm) has been reached.⁸⁹ The arthroscopy fluid inflow is then clamped to allow visual confirmation that blood and marrow fat droplets are emerging from each hole.

The success of the procedure depends as much on patient compliance with the rehabilitation protocol as it does on proper surgical technique. For lesions of the weightbearing surfaces of the femoral condyle and tibial plateau, the patient remains strictly nonweightbearing for 6 weeks and on protected weightbearing for an additional 2 weeks. Early passive motion is implemented. For lesions in the patellofemoral joint, the patient is braced with a flexion stop of 30° to 40° to limit patellofemoral contact. The brace is removed only for therapist-supervised range of motion and strengthening. Surgeon adherence to and patient compliance with these postoperative limitations are paramount to the success of this procedure.

Following proper technique and postoperative protocol, this relatively benign, inexpensive outpatient procedure can provide symptomatic relief and functional improvement in properly selected patients without eliminating further treatment options should the microfracture fail. Optimal outcome has been noted in younger patients with smaller lesions and a well-defined history of trauma.³⁸ One explanation for this finding is that the marrow of younger patients has a greater number of mesenchymal

cells, and, with increasing age, the pluripotential cell count drops off precipitously. In addition, a traumatic lesion, in contrast to a degenerative one, is likely to be surrounded by normal cartilage outside the zone of impact, which allows for the creation of “shoulders” at the periphery of the lesion. Steadman et al recently reported a series of 72 patients with a mean 11-year follow-up who demonstrated significant subjective improvement in the Tegner, Western Ontario and McMaster Universities Osteoarthritis Index, Lysholm, and Short Form-36 (SF-36) scores. At 7 years, 80% of patients reported themselves as improved. Younger age (<45 years) at surgery was correlated with a better outcome.⁸⁸

Osteochondral Autograft Transfer

This technique involves transfer of an osteochondral plug from a relatively nonweightbearing region of the knee to restore a damaged articular surface. The application of the technique is limited by the amount of donor tissue available in the knee. Ideal indications include symptomatic, distal femoral condyle articular cartilage lesions with intact menisci and tibial cartilage in a nondegenerative joint with proper mechanical alignment. Although large lesions have been treated with this technique, we believe the ideal lesion size is 1 to 2 cm in diameter. Lesions up to 3 to 4 cm in diameter can be treated, although graft limitations tend to limit optimal indications to treating smaller lesions. The treatment of patella or tibial surface lesions as well as intact but loose International Cartilage Repair Society (ICRS) grade II OCD lesions would be relative indications.⁴⁶

The risk of donor site morbidity increases as more tissue is harvested. The typical site of harvest is the femoral intercondylar notch and the periphery of the lateral femur just proximal to the sulcus terminalis. Simonian et al⁸⁶ evaluated these 2 typical sites of harvest and found that they demonstrated significant contact pressure, although the clinical relevance is unknown. Garretson et al⁸¹ described low contact pressures on the medial trochlea and relatively low contact forces at the distal lateral trochlear ridge, near the sulcus terminalis, identifying this as a possible harvest location on the lateral trochlea. Topographic mapping of the articular surface may allow for selection of donor sites to create plugs whose contour matches the recipient locations.⁶

All stages of the procedure, including graft plug harvest, recipient tunnel preparation, and plug insertion, can be done through a small arthrotomy or arthroscopically, depending on the location of the lesion. There are several commercially available systems to perform this procedure. A sizer is used to determine the number and size of grafts that will be needed. The properly sized graft harvester with collared pin is introduced perpendicular to the donor site. It is lightly tapped into bone to a depth of approximately 12 to 15 mm (Figure 3). For removal, the harvester is twisted abruptly 90° clockwise and counterclockwise with a parallel pull to remove the donor plug. The harvester has a plunger that will push the donor plug into the recipient hole.




Figure 3. Osteochondral plug autograft harvester seated in donor site on lateral aspect of lateral femoral condyle of left knee, demonstrating desired 12-15mm depth.

The recipient hole is created at a depth of 2 mm less than the donor graft just harvested and extracted in the same manner as the donor core. It is important to maintain a perpendicular relationship with the articular surface to create well-defined vertical walls in the recipient hole (Figure 4), which will facilitate congruent plug placement. This requires a constant knee flexion angle and often multiple accessory portals; implanting the graft plug immediately after harvesting will facilitate maintaining the proper insertion angle. The donor tube harvester is then placed over the recipient site, taking care to maintain perpendicular orientation, and the donor plug is gently advanced atraumatically into the defect, often leaving the plug slightly proud (Figure 5A). Premature advancement of the plug before it is well seated in the recipient tunnel may result in loss of control of the plug and may require plug collection using loose body retrieval techniques. The final seating of the plug can be done with an oversized tamp, taking care not to damage the articular cartilage on the surface of the plug graft (Figure 5B). The final plug position should be flush with the surrounding articular cartilage (Figure 5C). Graft congruence is key to minimizing shear. Studies indicate that tunnel depth should equal plug length precisely. Supported grafts heal well, but unsupported grafts tend to subside, eventually becoming covered by fibrous tissue.^{72,83}

If performing several transfers in a single lesion, the location of all plugs should be planned before placing the first one to minimize risk of tunnel confluence or tunnel wall fracture. Beginning at the periphery of a lesion, location and depth of the recipient tunnels and donor plugs are selected to create a convexity to match the surrounding joint surface.

Postoperatively, passive and active range of motion is encouraged. The patient is kept on protective weightbearing for up to 6 weeks. Graft healing is assessed both clinically and by plain radiographs to evaluate bone plug position and integration. Cartilage-specific MRI scans are

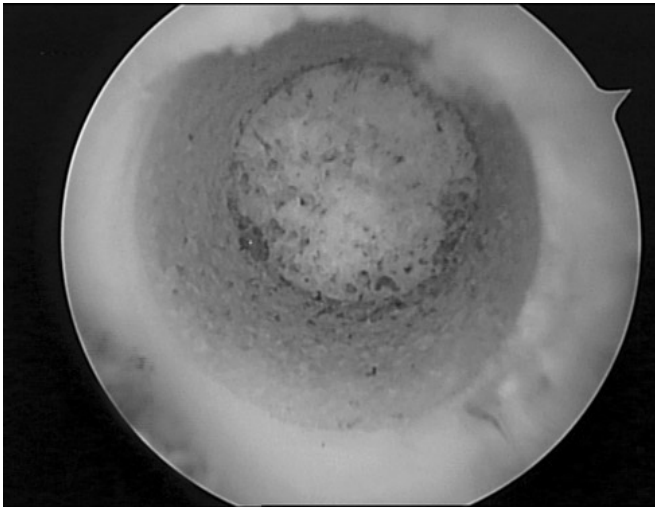


Figure 4. Autograft recipient hole on the medial femoral condyle of the left knee should have well-defined vertical walls.

helpful at 3-month intervals. After evidence of bone healing on radiographs at 6 to 8 weeks, the patient is advanced to full weightbearing as tolerated. Closed chain strengthening exercises only are allowed for 3 months to prevent undo shear on the articular surface.

The greatest amount of shear is seen at the interface of the donor plug and the recipient bed of cartilage, and a slightly prominent plug causes more shear than does a slightly recessed plug.¹⁹ Animal studies have demonstrated chondrocyte loss in areas of high shear at the edges of implanted plugs.⁵⁰ Perhaps combining microfracture and autologous plug transfer would provide a fibrocartilage interface for improved graft integration, reduced shear, and improved graft strength. Pull-out strength of properly placed press-fit plugs averages 93 N and correlates with plug length. It has been demonstrated that the force required to dislodge the graft is reduced by half with graft reinsertion or levering at the time of harvest.²⁵

The advantages of using autologous plug transfer to treat focal chondral lesions are graft availability (ie, there is no ordering or waiting for grafts), the absence of disease transmission risk, and the relatively low cost of a single-stage procedure. The disadvantages include donor site morbidity and limited available graft volume.^{25,45,46} In addition, it is technically difficult to position the plugs to re-create the contour of curved surfaces. Despite these limitations, in small- and medium-size lesions, this technique has been reported to result in 91% good to excellent results after more than 3 years for femoral condyle lesions that are isolated,^{25,42,45} if combined with ACL reconstruction,¹² or as treatment of OCD.^{13,47} Overall, autologous osteochondral plug transfer has been shown to result in a greater percentage of good to excellent results for femoral condyle lesions (92%) than for tibial plateau (87%) or the patellofemoral joint surface (79%).⁴⁵

Autologous osteochondral transfer is often used to treat focal lesions in other joints as well. Encouraging results have been reported in treatment of OCD of the talus⁴⁷ at

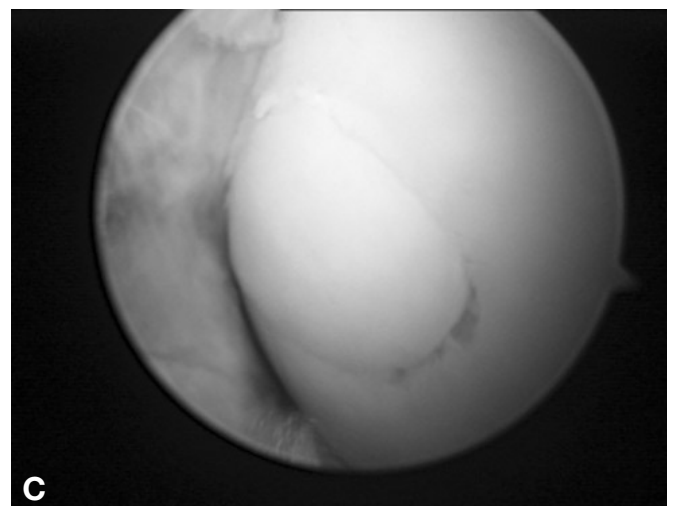
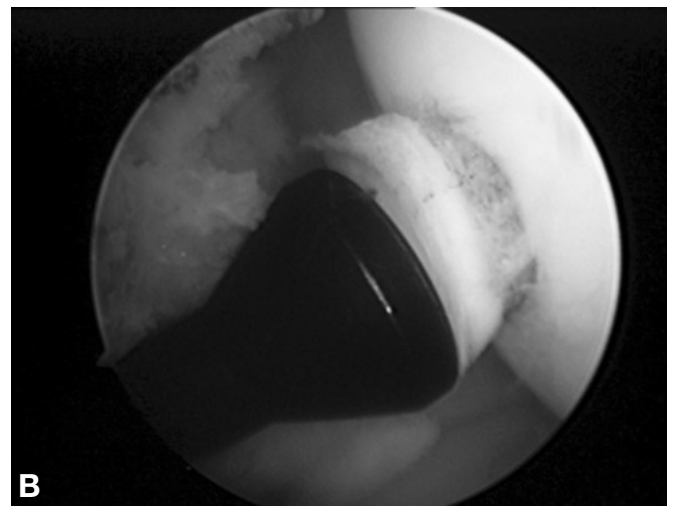
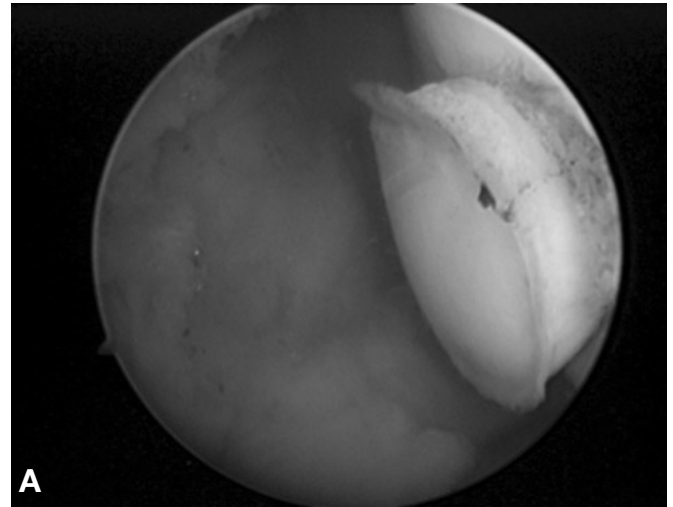


Figure 5. To protect graft viability and plug structure, the plug is inserted gently into graft site, often temporarily leaving a proud plug (A). An oversized tamp (B) is used to completely seat the autograft plug to create a flush surface on the femoral condyle (C).

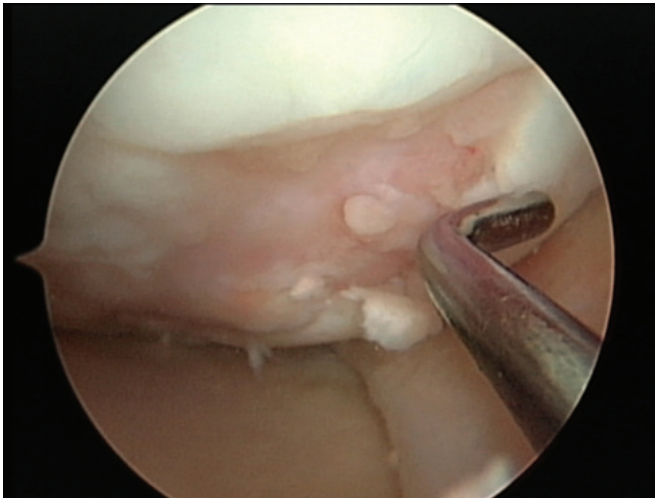


Figure 6. Arthroscopic evaluation of focal chondral lesion provides direct measurement and evaluation of containment and potential bone loss.

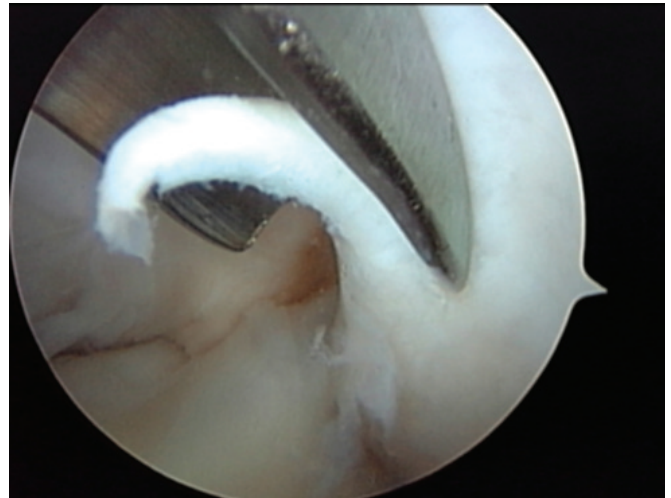


Figure 7. Arthroscopic biopsy of articular cartilage cells taken from nonweightbearing portion of lateral femoral condyle in a left knee.

up to 7 years after treatment. In treating traumatic focal chondral lesions of the talus, autologous plug transfer resulted in a favorable outcome in 94% of patients when compared to marrow-stimulation techniques (ie, microfracture).⁴⁴ In addition, reports of the use of osteochondral transfer to treat focal chondral lesions in the femoral head⁴⁵ and elbow OCD¹³ demonstrate encouraging results.

Further refinements of this technique will minimize donor site morbidity by careful selection of the harvest site. In the future, a refined technique may avail autologous hyaline cartilage plugs to treat focal chondral defects in any synovial joint with hyaline cartilage. Just as the iliac crest has become the utility source of autogenous bone graft, so too may the relatively nonweightbearing surfaces of the femoral condyle provide osteochondral plugs for routine transfer to other joints.

Autologous Chondrocyte Implantation

Autologous chondrocyte implantation (ACI) is employed when traditional first-line treatments fail to improve on the patient's clinical presentation after adequate time for recovery and response. It is ideal for symptomatic, unipolar, well-contained chondral or shallow osteochondral defects measuring roughly 2 to 10 cm². Commonly, patients have failed previous treatments. It is traditionally indicated for treatment of focal defects in the knee, but its "off-label" use has recently been expanded to include the treatment of chondral defects in the ankle,^{34,56} shoulder,⁷⁸ elbow,¹³ wrist,⁷⁰ and hip.⁵¹ In the knee, off-label use for the patella and tibia has also met with success rates that parallel those for the femoral condyle and trochlea. Bipolar lesions (greater than grade II change on the opposing surface) are a relative contraindication to ACI. As already discussed, malalignment, ligament instability, and meniscus deficiency are not considered absolute contraindications to ACI as long as they are addressed concomitantly or in a staged fashion.

The first stage involves an arthroscopic evaluation of the focal chondral lesion to assess containment, depth, and potential bone loss (Figure 6). Biopsy of normal hyaline cartilage is performed from either the superomedial edge of the trochlea⁶⁴ or our preferred site, the lateral edge of the intercondylar notch (ie, where bone is removed for an ACL notchplasty) using a curved bone graft harvesting gouge (Figure 7). If the biopsy is obtained from the trochlear ridge, it is recommended that an open-ring curette be used to allow for visualization of the biopsy process. The total volume of the biopsy should be approximately 200 to 300 mg, preferably in 3 "Tic-Tac-sized" fragments. The prepared shipping container has a collection vial that is clearly marked to indicate adequate biopsy volume (Figure 8). As when performing an ACL notchplasty, it is important not to violate weightbearing articular cartilage. We send the biopsy to Genzyme Biosurgery Corporation (Cambridge, Mass) for processing and cellular expansion.

The second stage of the procedure is cell implantation, which typically takes place between 6 weeks and 18 months after the biopsy, although the cells can be cryopreserved for up to 4 years. A tourniquet is typically used until after the defect is prepared and the periosteal patch is harvested. The surgical exposure depends on defect location. Patellofemoral lesions are approached through a midline incision, allowing a simultaneously performed tibial tubercle osteotomy. We prefer to access patellofemoral lesions through a lateral retinacular release without completely everting the patella. We also avoid disruption of the fat pad and dissection around the patellar tendon to reduce potential for postoperative stiffness. A tibial tubercle osteotomy affords some increased patellar mobility, facilitating access to the defect, but we intentionally avoid complete elevation and "flipping" of the tibial tubercle to minimize trauma to the fat pad and patellar tendon.

Femoral condyle lesions are addressed through limited parapatellar arthrotomies. For medial defects, we use a

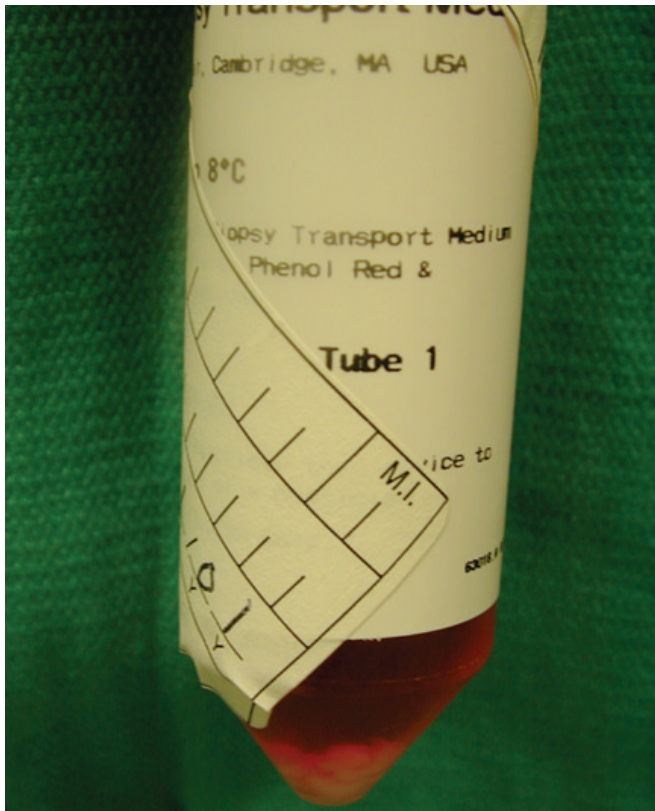

Figure 8. Prepared shipping vial, demonstrating collection well to assess adequate biopsy volume.

limited sub-vastus medialis approach that has, in our experience, reduced the magnitude of postoperative pain, allowing earlier and more complete return of motion. Lateral defects are approached through a limited lateral retinacular release. We then use a separate 3-cm incision beneath the pes anserine tendon insertion to harvest the periosteal patch. These modifications have greatly reduced postoperative pain and have allowed us to perform the majority of our ACI procedures on an outpatient basis.

Defect preparation involves removing any existing fibrocartilage covering the lesion, as well as loose articular cartilage flaps, leaving healthy surrounding hyaline cartilage to form stable vertical walls shouldering the lesion. Circular or oval-shaped prepared defects are biomechanically more stable.²⁴ A No. 15 scalpel and sharp-ring curettes are used to incise the defect border to but not through the level of the subchondral bone (Figures 9 A and B). Hemostasis is controlled with the use of neuropatties soaked with a dilute 1:1000 epinephrine solution.

The periosteal patch is harvested through a 3-cm incision on the proximal medial tibia, 4 fingerbreadths distal to the pes anserine tendon attachments. More distal and anteromedial locations tend to provide the best source for the periosteal patch. If a simultaneous tibial tubercle osteotomy is performed, we use a single extensile incision and harvest the periosteum before performing the osteotomy. Superficial subcutaneous fat is carefully removed with sharp dissection from the periosteum on the anteromedial

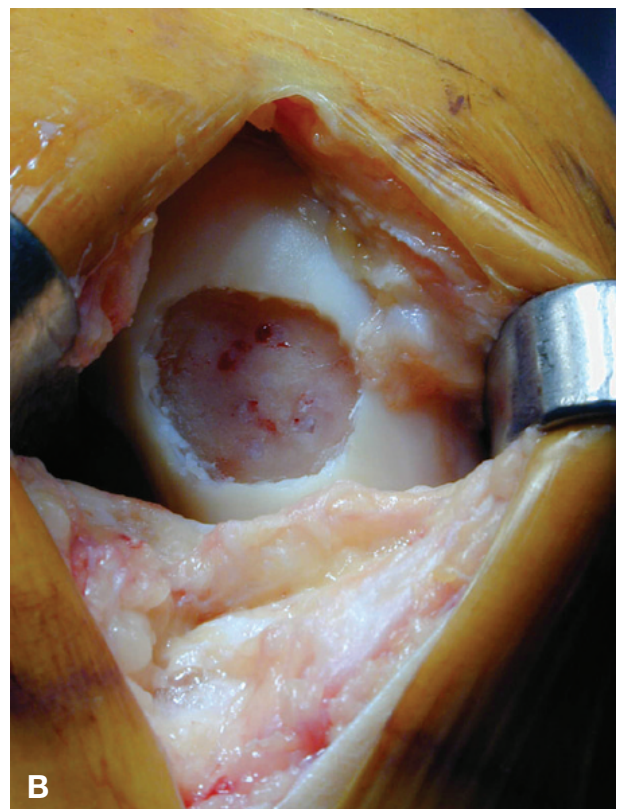
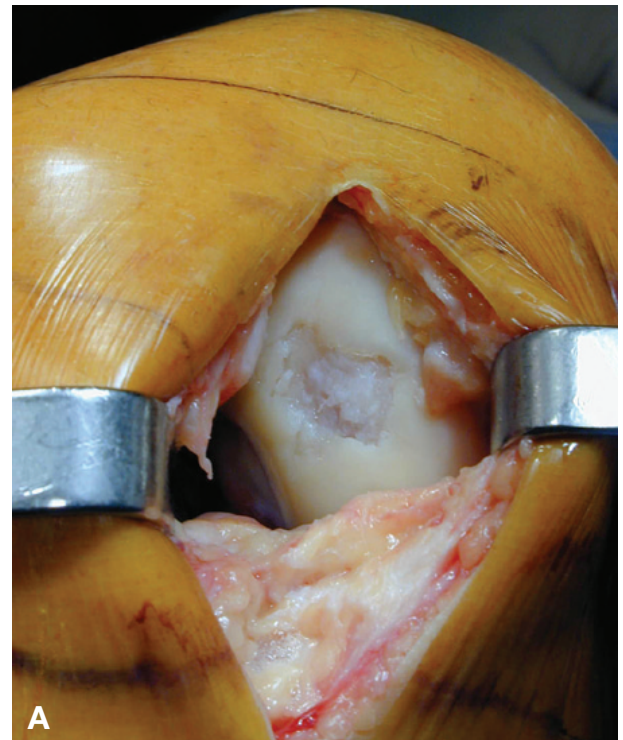


Figure 9. Focal chondral defect on the medial femoral condyle of a right knee before (A) and after (B) preparation.

tibia to avoid inadvertent penetration. Smokers tend to have a poor-quality periosteum, and obese patients have a

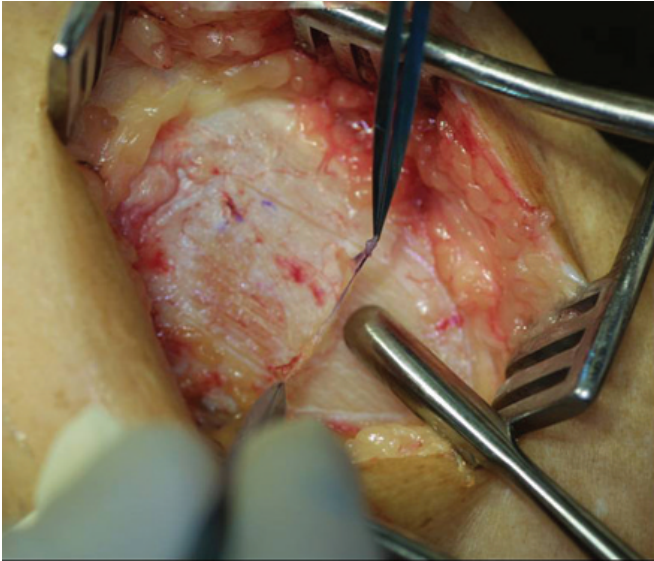


Figure 10. Periosteal harvest from anteromedial tibia, using curved-tipped elevator to minimize risk of penetrating periosteum during harvest.

larger amount of adherent adipose tissue to separate from the periosteum and will require extra care. In addition, older patients tend to have a thin periosteum. A patch that is at least 2 mm larger than the defect is harvested to allow for slight shrinkage after detachment. The patch edges are scored to bone with a No. 15 scalpel and elevated with a sharp, curved periosteal elevator beginning distally and moving toward the inferior edge of the pes and overlying sartorius fascia (Figure 10). The character of the periosteum will change as the sartorius fascia fibers are encountered. It is recommended that the fat and small blood vessels found on the periosteum be dissected off after the periosteum is safely elevated from the bone but before detaching the final superior edge. The outer surface is marked to distinguish it from the inner cambium layer. Additional sources for periosteum, if necessary, are the distal femur, which is thicker and more vascular than the periosteum on the proximal tibia, and the contralateral tibia, which carries the disadvantage of a second surgical site. In extreme cases, 2 periosteal patches may be sewn together, taking care to minimize suture bulk at the seam.

After defect preparation and periosteal harvest, the tourniquet is deflated and meticulous hemostasis is obtained. The patch is then sewn onto the cartilage so as to remain taut over the defect with the cambium layer facing the defect base. The periosteum is secured with a 6-0 absorbable Vicryl suture (Ethicon Inc, Johnson & Johnson, Somerville, NJ) on a P-1 cutting needle. The suture is passed first through the periosteum patch and then through the articular cartilage. The goal is to anchor the periosteum flush with the surrounding articular cartilage surface. A gap should be maintained between the final sutures to allow for chondrocyte implantation with an angiocatheter. If small holes are inadvertently created in the patch, they may be carefully repaired with a single 6-

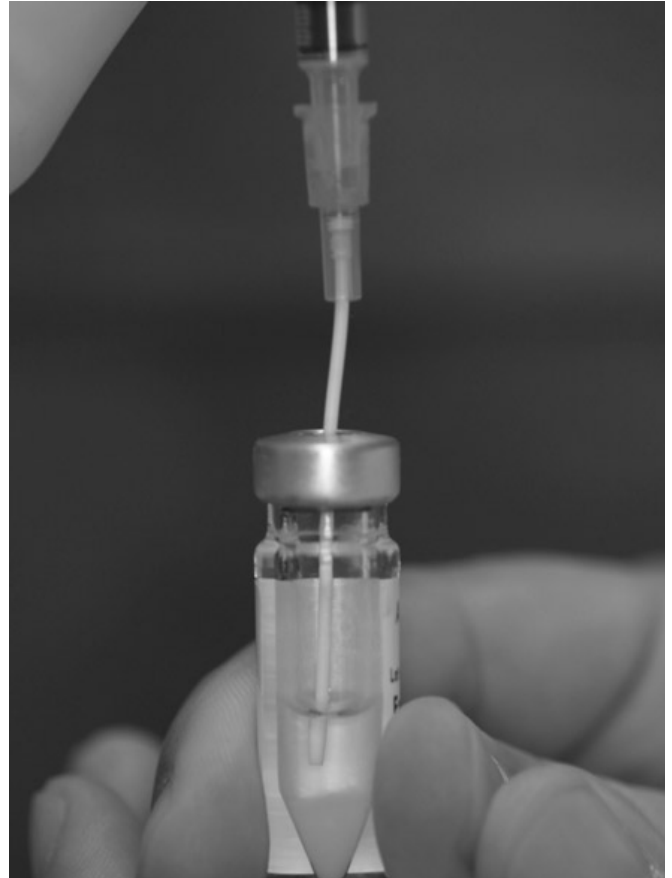


Figure 11. The angiocatheter tip is submerged in fluid while the vial containing chondrocytes is held vertical. Meticulous attention to sterile technique during this step is paramount.

0 Vicryl suture. If the surrounding cartilage is unable to hold suture, micro-anchors loaded with absorbable suture may be used. At the edge of an articular surface, bone tunnels may be created with a 0.45 Kirschner wire to pass transosseous 6-0 sutures.

Watertightness testing is performed with a nonantibiotic saline-filled tuberculin syringe and 18-gauge catheter. After the saline is injected for the watertightness test, it should be removed completely. Additional sutures are placed at leakage locations, and after gently drying the cartilage surrounding the patch, the edges of the patch are sealed with fibrin glue (Tisseel, Baxter Healthcare Corp, Glendale, Calif) and a second watertightness test is performed as previously described.

The chondrocytes are delivered and stored in vials that should remain upright at all times. Meticulous attention to sterile technique is paramount during this step, as the vial's exterior is not sterile. The vials are held in a vertical position without disturbing the pellet of cells in the bottom of the vial. An 18-gauge angiocatheter is inserted into the vial and advanced so the tip is submerged in the fluid but above the pellet of cells in the bottom of the vial to allow repetitive gentle aspirations and reinjections of the fluid to atraumatically suspend the chondrocytes (Figure 11). The

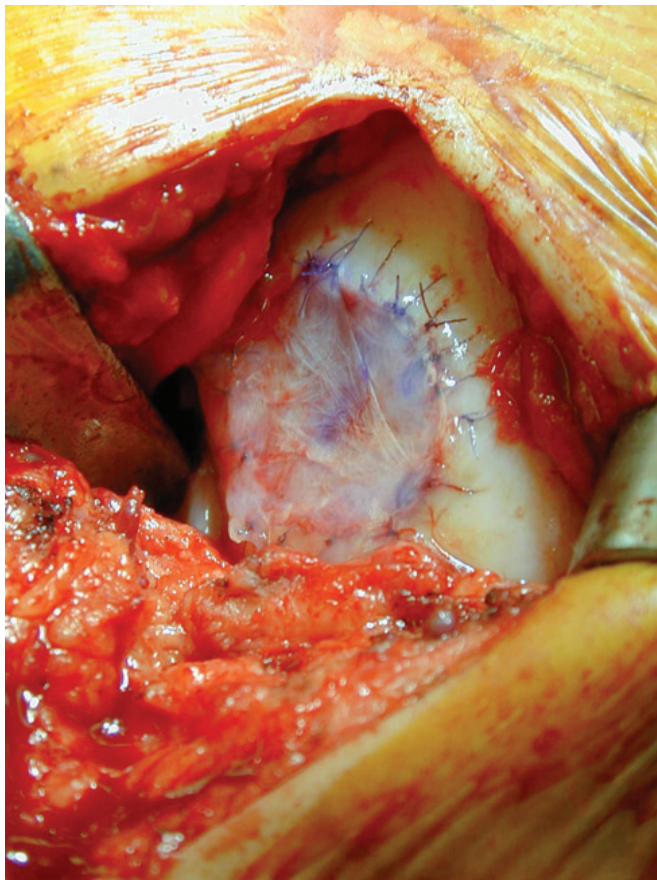


Figure 12. After cell implantation, the sutured periosteal patch is sealed with fibrin glue.

total volume of the homogeneous suspension in the vial is then drawn into the syringe. A new sterile angiocatheter tip is used for the implantation step.

To implant the cells into the prepared defect, the catheter is placed through an opening at the top of the periosteal patch and advanced to the distal end of the defect. The cells are slowly injected into the bed of the defect to ensure even dispersal while the catheter is slowly withdrawn. The opening is then closed with additional sutures and sealed with fibrin glue (Figure 12).

Technical Considerations. Most defects are easily accessible on the weightbearing surface of the femoral condyle through a standard parapatellar arthrotomy. However, far posterior condylar lesions or focal cartilage defects of the tibial plateau may require additional strategies for exposure, including an open submeniscal approach or even en bloc osteotomy of the collateral ligaments.

Traditionally, ACI has been applied to treat relatively shallow articular cartilage lesions with minimal involvement of the subchondral bone. For osteochondral defects of more than 8 to 10 mm in depth, bone grafting is recommended. The bone graft may be performed at the time of biopsy and the implantation delayed to allow for bone graft consolidation. Alternatively, the “sandwich tech-

nique” has been used to graft and resurface the defect in a single step. A layer of periosteum is sealed against the grafted defect with the cambium layer facing outward toward the joint and fixed with 6-0 Vicryl sutures (Ethicon Inc) and fibrin glue. A second periosteal patch is placed with the cambium layer facing into the defect, creating a cambium-lined chamber overlying the bone graft. The chondrocytes are then injected between the 2 layers of periosteum. A complete description of the procedure is reported elsewhere.¹⁵

It is commonly believed that for all of these techniques, realignment osteotomy should be performed as an adjunct procedure if the lesion is in a compartment under more than physiological compression.⁴² Outcome data clearly indicate that poorer results are expected if mechanical axis or patellofemoral joint malalignment is left uncorrected at the time of the cartilage restoration procedure.¹⁵

The rehabilitation protocol for ACI in the knee is based on the 3 phases of the natural maturation process of the chondrocytes.^{37,65,66} The proliferative phase occurs soon after the cells are implanted, followed by the matrix production phase, during which the tissue becomes incorporated and integrated into the host. To assist cellular orientation and to prevent adhesions, early passive motion is crucial. The graft must be protected from mechanical overload; closed chain strengthening exercises are initiated to allow for a functional gait. Continuous passive motion for 6 to 8 hours per day at 1 cycle/min and restricted weight-bearing are required until 4 to 6 weeks, when progression to full weightbearing is allowed. The third recovery phase is the maturation phase, which results in stiffness closely resembling the surrounding articular cartilage. During this extended phase, various impact loading activities are phased in with increased strength work. Return to normal activities of daily living and light sporting activity is considered at 4 to 6 months.

Outcomes of ACI in the Knee. It is estimated that ACI has been performed on 10 000 patients worldwide.¹⁵ Micheli et al⁶³ reported on 50 patients who were followed for a minimum of 36 months and demonstrated a significant subjective improvement of 5 points on the modified Cincinnati scale measuring overall knee function (10-point scale). Eighty-four percent had an improvement in their conditions, 2% were unchanged, and 13% deteriorated. One third of these patients had failed a previous marrow-stimulation procedure. Peterson et al⁷⁵ published their results on 94 patients with 2- to 9-year follow-up. The results varied considerably based on defect location. The results of ACI when treating the patella initially were only 62% good to excellent. However, later in the series, antero-medialization tibial tubercle osteotomies were performed simultaneously when treating patellar lesions, and results improved to 85% good or excellent. Twenty-four of the 25 isolated femoral condyle lesions were graded as having good to excellent results with a 92% success rate. In the OCD group, 16 of 18 patients were rated good to excellent, representing an 89% success rate. The majority of follow-up biopsies revealed objective evidence of hyaline-like tissue that demonstrated type II collagen on immunohisto-

chemical staining. In 10% to 15% of cases, the biopsy site demonstrated an exaggerated healing response in the notch, resulting in discomfort and catching, which may occur between 3 and 9 months. This routinely responded well to simple arthroscopic debridement.

To study the long-term durability of ACI, Peterson et al followed 61 patients for a mean of 7.4 years after ACI. Good or excellent subjective results were found in 81% at 2 years and 83% at 5- to 11-year evaluation. The total failure rate was 16%, all of which occurred in the first 2 years. In this series, patients with the longer outcome were early patients who underwent ACI before full maturation of the surgical technique. As all failures occurred before 2 years, this study illustrated the durability of results at 2 years.⁷³

Cole et al²² reported on a series of 103 defects in 83 patients who had been evaluated prospectively after their ACI procedures. Cincinnati, International Knee Documentation Committee, Tegner, Lysholm, Knee Injury and Osteoarthritis Outcome, and SF-12 physical scores all showed significant ($P < .05$) subjective improvement in 30 patients evaluated at a minimum of 2 years compared to preoperative ratings. Although patients were not pain free, nearly all reported approximately a 50% reduction in pain. In this series, patient satisfaction was high; 79.3% stated that they were completely satisfied, and 92.9% stated that they would have the surgery again, given similar circumstances.

To compare microfracture to ACI, Knutsen et al⁵⁵ randomized 80 patients with single focal chondral defects in stable, nonarthritic knees with proper mechanical alignment to receive either ACI or microfracture as a primary treatment. At 2 years, objective arthroscopic evaluation and biopsy combined with subjective clinical evaluation using Tegner, Lysholm, ICRS, and SF-36 demonstrated significant improvement in both groups, with statistically significantly greater improvement in the microfracture group than in the ACI group ($P = .004$). Younger and active patients did better in both groups. In this series, both groups of patients were allowed immediate partial weight-bearing (up to 50 lb), which may have been disruptive for the fragile ACI patch.

Horas et al⁴⁹ compared ACI to osteochondral autograft transplantation at 2 years in 40 patients with a single femoral condyle chondral defect. Both treatments decreased symptoms, but the subjective improvement provided by ACI lagged behind that provided by the osteochondral autograft transplant. Objective histologic data revealed that the ACI tissue was primarily fibrocartilage, whereas the osteochondral transplants retained their hyaline character. There was a persistent gap and lack of integration between the bone plugs and the surrounding articular cartilage. This study had a small number of patients in each group, a relatively short follow-up, and no control group.

To compare mosaicplasty to ACI, Bentley et al⁸ randomized 100 patients with a mean age of 31 years with isolated traumatic focal chondral defects to receive either ACI or mosaicplasty. Modified Cincinnati scores and clinical assessment measures showed subjective good to excellent results in 88% of ACI patients and only 69% of the mosaicplasty patients. Objective arthroscopic visualization at 1

year demonstrated 82% healing among ACI patients but only 34% healing among mosaicplasty patients. This is the only prospective, randomized, controlled comparison of ACI and mosaicplasty and appears to demonstrate the superiority of ACI over small-plug autologous mosaicplasty.

Autologous Chondrocyte Implantation in Other Joints. Although ACI technology has traditionally been applied to treat focal chondral lesions in the knee, it has recently been used to treat lesions on other joint surfaces. Unpublished reports of resurfacing a femoral head defect (Lars Peterson, J.W.A. personal communication, December 7, 2003) and published reports of using ACI to treat elbow lesions^{13,15} are emerging. The senior author recently reported the use of ACI to treat a young athlete with a large full-thickness 6-cm² articular cartilage defect of the proximal humerus.⁷⁸

In addition to the shoulder, ACI technology has recently been applied to treating osteochondral defects of the talus. Because of the traumatic nature of these lesions, the osteochondral fragment of the talus is carefully evaluated during an initial ankle arthroscopy, and a decision whether to attempt fixation is made. Successful results of fixation efforts overall are reported to be between 36% and 81% and are more thoroughly discussed elsewhere.^{5,53,79} After completion of the ankle arthroscopy, an arthroscopic articular cartilage biopsy is obtained from the ipsilateral knee. In evaluating the chondral lesion, important variables to consider include the size and dimensions of the lesion, the location of the lesion, and whether an osteotomy would be required for an open exposure for an ACI procedure. The need for bone grafting via the "sandwich technique" can also be predicted and is determined by the depth of the talar lesion. The need for osteotomy of the medial or lateral malleoli at the time of cell implantation depends on both the size and location of the defect.

Comorbidities of the ankle including instability or fractures requiring fixation must be carefully evaluated, and the decision to perform a concomitant ankle stabilization procedure should be predetermined and incorporated into the surgical plan. If the patient would benefit from lateral ligament reconstruction, then this is carried out in conjunction with the ACI procedure in a single stage. If the patient has an OCD in the anterolateral aspect of the talus, the lateral ligament reconstruction can be performed at the completion of the ACI implantation via the same anterolateral incision. Treating an OCD lesion at a second location on the talus will likely require an osteotomy.⁶¹ Once surgical exposure and a plan for treating comorbid conditions are established, lesion preparation, periosteal harvest, graft suturing, and cell implantation are performed according to standard ACI protocol as described above.

Postoperatively, the patient is placed in a hinged ankle brace that allows for a 20° arc of dorsiflexion and plantar flexion. Continuous passive motion is initiated 8 hours postoperatively. The patient is permitted toe-touch weight-bearing during the first 2 weeks and is progressively increased to 75% weightbearing at the end of 6 weeks and to full weightbearing by 8 weeks. At 6 months, a gradual

return to jogging and sport-specific training may be initiated.

To date, there are 3 published series of reported subjective improvement after ACI as treatment of chondral lesions of the talus. Giannini et al³⁴ reported the outcomes of 8 patients who were treated with ACI as a second-line treatment, and in their series, American Orthopaedic Foot and Ankle Society scores improved from 32 points preoperatively to 91 points at 2 years after implantation. In 2002, Koulalis et al⁵⁷ reported on 8 patients at a mean of 17 months who also universally reported subjective improvement after failing other treatments, despite no objective evidence of type II collagen at follow-up biopsy. Mandelbaum et al⁶¹ recently reported a series of 14 patients at 32 months with 79% good and 21% poor outcomes; half of the patients in this series required arthroscopic debridement for periosteal patch hypertrophy.

Future Directions for ACI. In the future, techniques using minimally invasive implantation will spare the patient the morbidity of an open arthrotomy. All-arthroscopic techniques have been reported but are not currently implemented in the United States.²⁶ The technique is based on implanting a 2-mm-thick polymer fleece preloaded with autologous chondrocytes in a fibrin gel that is anchored to the condyle arthroscopically. Other techniques have implemented in vitro culturing of a chondrocyte-laden scaffold before implantation.⁵⁹ In a canine model, Lee et al⁵⁹ evaluated full-thickness focal chondral defects without bone involvement 15 weeks after implantation of an autologous articular chondrocyte-laden type II collagen scaffold that had been cultured in vitro before implantation. In these cultured scaffolds, the reparative tissue formed from the scaffolds filled 88% of the cross-sectional area of the original defect, with hyaline cartilage accounting for a mean of 42% (range, 7%-67%) of the defect area. Further work is necessary to identify the specific culture and cell density parameters needed to maximize this advantage of in vitro scaffold culture before final implantation compared to the results of noncultured implantation.^{14,74} In the future, allogenic sources of cells or single-stage biologic techniques may offer the added advantage of eliminating the need for biopsy before implantation.

Osteochondral Allograft Transplantation

To treat large lesions (ie, 2.5 cm²) or those with significant bone loss, osteochondral allograft transplantation provides a valuable treatment option. The advantage of osteochondral allografts is the ability to provide fully formed articular cartilage without specific limitations with respect to defect size. In addition, there is no concern for donor site morbidity. Potential disadvantages include graft availability, cell viability at the time of implantation, immunogenicity, and the potential for disease transmission. A more complete discussion of allograft tissue processing can be found in part 1 of this 2-part "Current Concepts" article.

Although there is no specific limitation as to the largest size of a defect that can be treated with an allograft, the minimum size is debated. Although surgeons have used

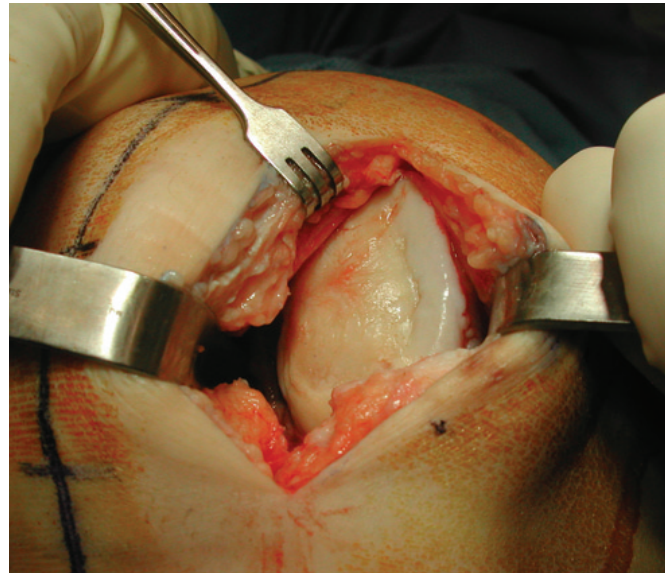


Figure 13. Chondral lesion with bone involvement on the medial femoral condyle of the right leg.

allografts to treat lesions as small as 1 cm², most reports recommend the lesion be 2 to 3 cm² or greater.^{20,32,33,41} The ultimate decision of limits of graft size and patient age will require a careful measure of risks and benefits with respect to each specific patient's needs.

Technique. In many cases, a medial or lateral peripatellar mini-arthrotomy can be used to expose the lesion. The lesion is then assessed to determine the graft shape that would best fit the defect. Well-contained, centrally located lesions can generally be replaced with a dowel-shaped graft (Figure 13). An instrumentation system (Arthrex Inc, Naples, Fla) is used to size and harvest a cylindrical graft plug from the allograft. Because of the close tolerance between the donor plug and recipient socket that results from this technique, it is usually possible to press fit the graft, eliminating the need for supplemental internal fixation.

The diameter of the defect is matched to the sizing cylinder (range, 12-35 mm) that best incorporates the majority of the defect. The sizing cylinder is held centered and perpendicular to the defect, and a guide pin is drilled in the center of the lesion to a depth of 2 to 3 cm. While the joint is irrigated with normal saline, the cannulated counter bore is drilled over the pin to create a cylindrical defect to a depth of 8 to 10 mm, and the bottom of the prepared defect is penetrated with a small drill to create vascular access channels (Figure 14). Bone depth is limited to between 8 and 10 mm to facilitate graft implantation and to limit the volume of immunogenic donor bone implanted. Shallower grafts will not achieve adequate press fit. A sterile marking pen is used to mark the 12-o'clock position of the lesion to appropriately orient the donor plug, as the depth of each quadrant of the recipient lesion is measured and used to tailor the exact depth of the final cut of the donor plug.

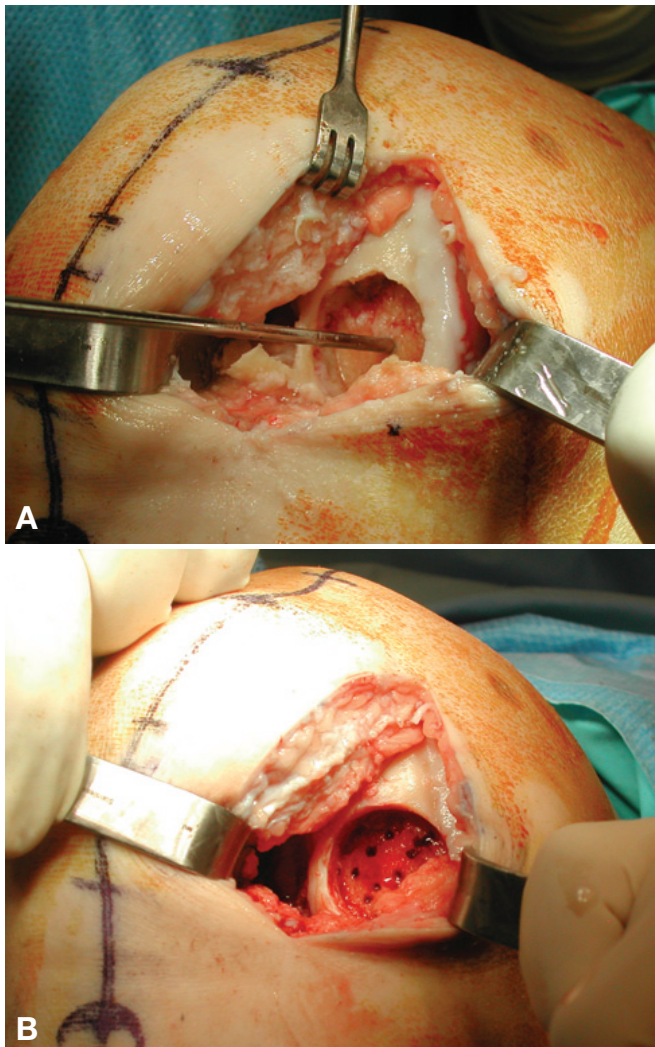


Figure 14. Defect preparation (A) with guide pin in place to identify perpendicular orientation to articular surface and (B) after creation of vascular access channels.

If an entire hemicondyle is made available, it is first sectioned to create a flat surface perpendicular to the proposed harvest site (Figure 15). The allograft is secured in the allograft workstation. The bushing is secured such that the contour of the donor site matches the contour of the recipient site from a low-angle side view of the workstation, using the sizing cylinder for orientation (Figures 16 A-C). Although matching the location of the defect on the donor condyle is preferred, defects smaller than 2 cm² are easily matched from most regions of the hemicondyle. The 12-o'clock position of the donor graft is marked. While irrigated with normal saline, the donor graft is then drilled through its entire depth with a harvester, and the graft is extracted. A ruler is used to measure and mark the graft at the depth of the 4 quadrants of the previously measured recipient site. Holding forceps are used to secure the allograft while it is irrigated and cut using an oscillating saw. To facilitate insertion, the edge of the allograft is slightly beveled with a rongeur. Before insertion, pul-

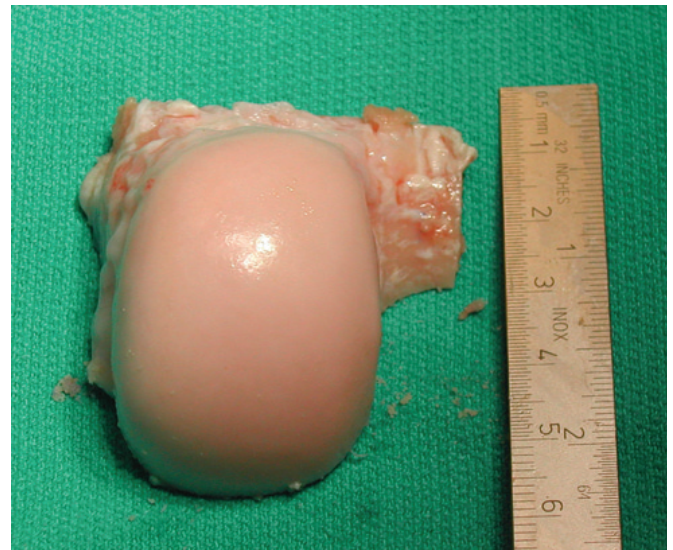

Figure 15. Allograft is cut to fit into the workstation anchor apparatus.

satile lavage is used to remove residual blood and bone marrow elements from the allograft, which further reduces the chance of disease transmission and graft immunogenicity.

A calibrated dilator is inserted in the recipient socket to dilate the socket an additional 0.5 mm. The graft is press fit into the socket by hand after carefully aligning the 4 quadrants to the recipient site. Further impaction is achieved with gentle use of an oversized tamp, remaining mindful that excessive force will damage chondrocytes. The goal is a secure, well-seated plug that matches the host contour and is flush with the surrounding articular surface (Figures 17 A and B). For large lesions, 2 or more allograft plugs may be placed tangentially. If the implanted allograft is particularly large, fixation may be augmented with bioabsorbable pins or metal screws. When necessary, we prefer a headless screw with differential thread pitch that provides low-profile compression, but it may need to be removed at a later date if not properly recessed.

If the lesion is not amenable to a cylindrical graft, a shell graft can be fashioned freehand, typically in a trapezoidal configuration that matches a hand-prepared defect bed using a motorized bur and oscillating saw with cold irrigation. Freehand sizing of a graft is more time consuming and usually requires fixation.

After osteochondral allograft implantation, restricted weightbearing is recommended for at least 8 weeks to protect the cartilage surface and to minimize the chance for subchondral collapse during the creeping substitution phase of graft healing. Continuous passive motion is used for 6 to 8 hours per day at 1 cycle/min for the first 4 to 6 weeks. Return to normal activities of daily living and light sporting activity is considered at 4 to 6 months. In general, high-impact sports are not recommended after osteochondral allografting for large articular cartilage lesions because of the theoretical risk of graft collapse and potential deterioration in the long-term survival of the graft.⁶⁹

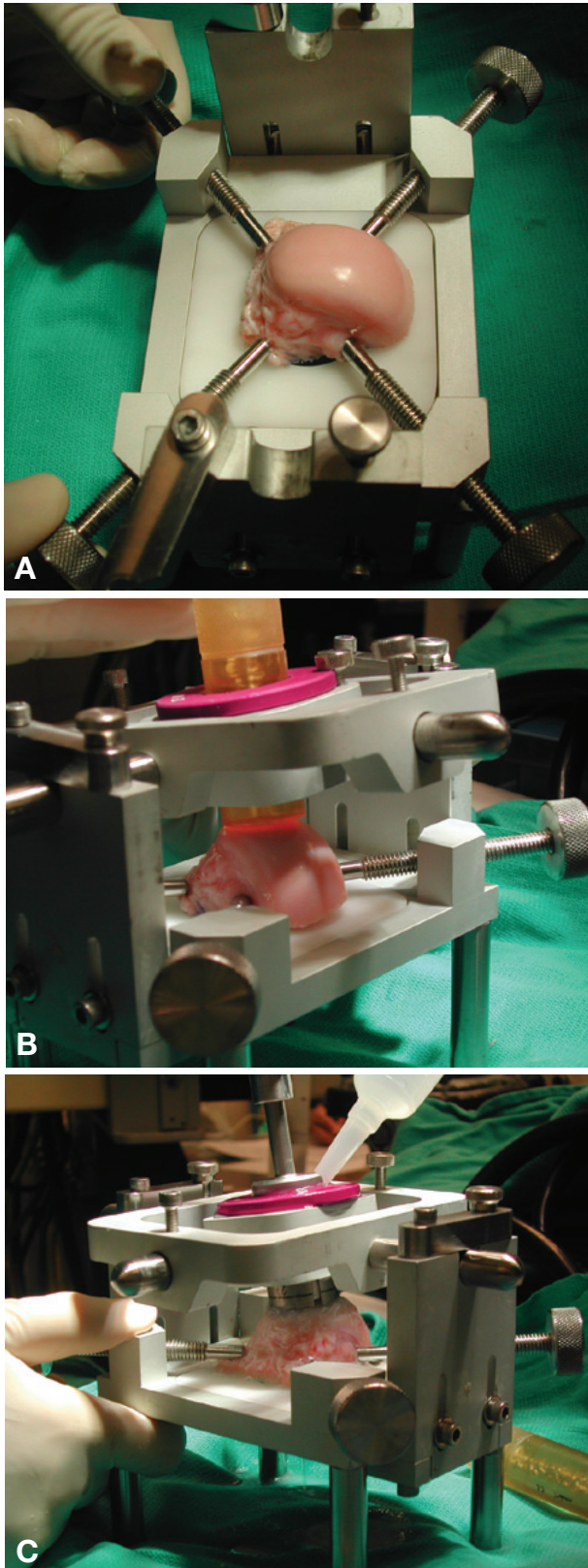


Figure 16. A, Allograft mounted in workstation. B, cutting guide is positioned to create a cylinder perpendicular to the allograft articular surface. C, the allograft is irrigated to prevent heat damage to the allograft tissue while the power cylindrical saw is used to create desired osteochondral plug.

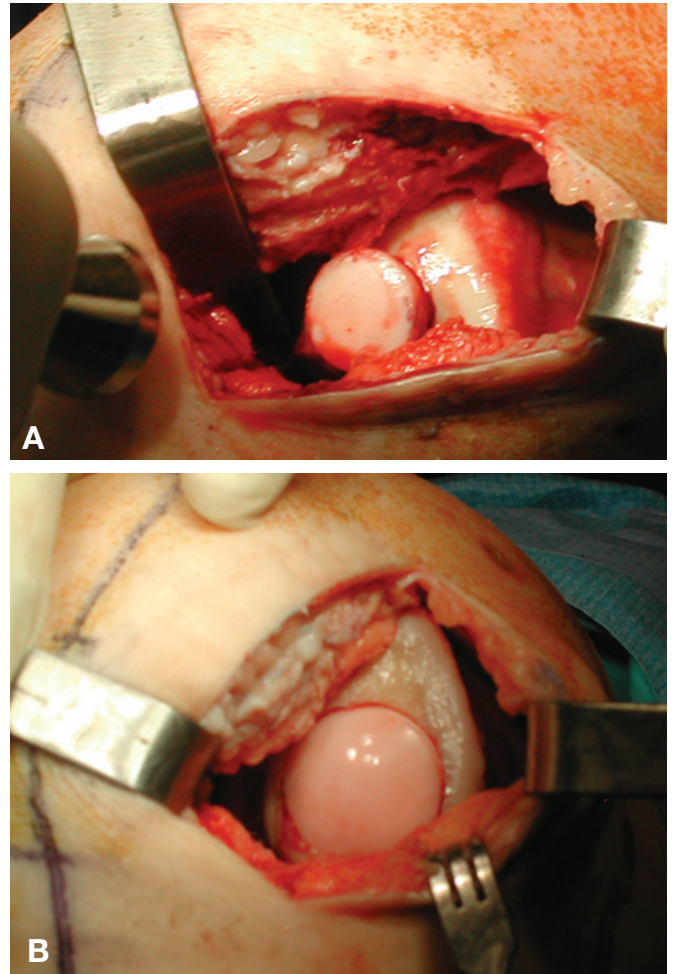


Figure 17. A, allograft press fit often requires gentle tamping to establish the proper depth of insertion. B, allograft implanted flush to host articular surface.

Outcomes of Osteochondral Allograft Transplantation. Clinical studies have indicated that younger patients with an isolated lesion secondary to trauma or OCD, and without other joint abnormality, tend to have more optimal outcomes after osteochondral allografting. In 1985, the University of Toronto reported the subjective outcomes of their first 100 fresh allograft shell grafts used to treat lesions of the femur, tibia, patella, and talus. At a mean of 3.8 years, modified HSS scores were good or excellent in only 56% overall. However, within this group, traumatic lesions had a 75% (36/48) success rate, whereas osteoarthritic lesions had 42% (10/24) success, and lesions from avascular necrosis had only a 27% (3/11) success rate.⁶² In 1999, Chu et al²⁰ reported the results of 123 patients with a purely traumatic cause to their articular cartilage lesions. In this series, a success rate of 86% was reported at a mean of 7.5 years. There was a survivorship of 95% at 5 years and 71% at 10 years. Early failure was found in patients older than 50 years, those with bipolar lesions or mechanical axis malalignment, or those on workers' compensation. In another series of OCD of the femur, 94% (16/17) of patients treated with 10 dowel grafts

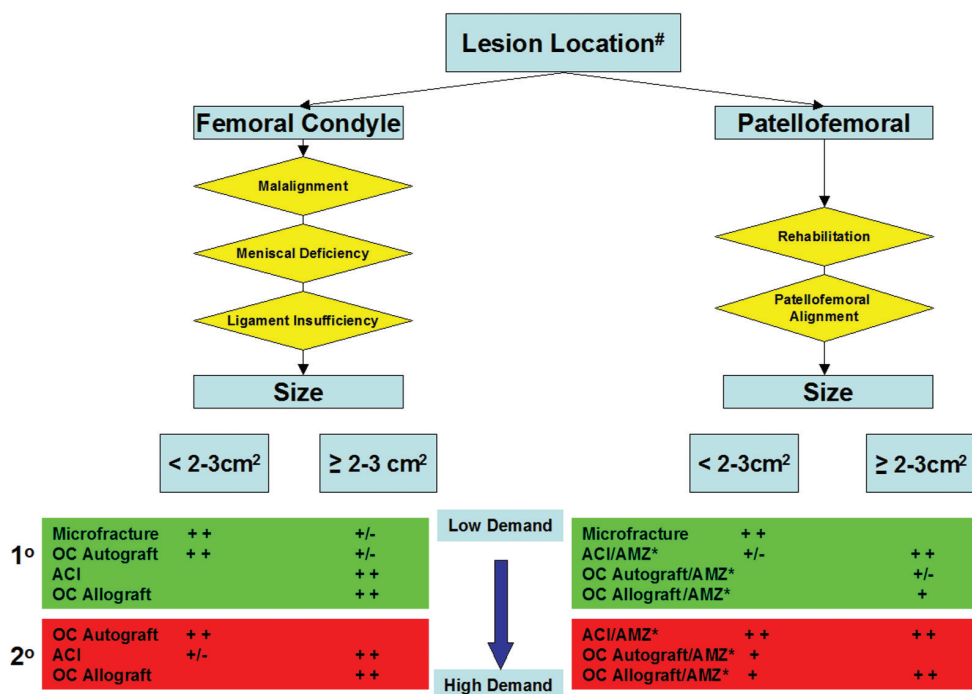


Figure 18. Treatment algorithms for isolated femoral and patellofemoral focal chondral lesions. For condylar lesions, comorbidities of ligament instability, meniscal deficiency, and malalignment must be assessed and corrected if needed. For trochlear and patellar lesions, surgical treatment should be considered after exhausting rehabilitation options. Patellofemoral alignment must be evaluated to select the proper angle of the anteromedialization tibial tubercle osteotomy. High-demand patients are more likely to require a secondary line of treatment (red). OC, osteochondral; ACI, autologous chondrocyte implantation; AMZ, anteromedialization tibial tubercle osteotomy. #Assumes minimal bone loss. *AMZ is often performed for lateral and central patellofemoral lesions and is of questionable benefit for medially located patellofemoral lesions. Osteotomy angle is selected by preoperative assessment of patellofemoral tracking and presence or absence of instability.

and 7 shell grafts were asymptomatic at a mean of 3.5 years.³² Bugbee¹⁶ reported on 211 knees at more than 4 years; femoral grafts had a 93% (116/125) success rate, patellofemoral grafts had 76% (35/46) success, but tibiofemoral bipolar lesions had only a 65% (26/40) success rate. Uncorrected ligamentous instability and mechanical limb malalignment were associated with worse outcomes.¹⁷

In summary, it is reasonable to expect subjective improvement in 75% to 85% of patients after osteochondral allograft implantation treatment of properly selected chondral lesions, provided that the surgeon practices careful patient selection and accurately identifies and corrects concomitant knee abnormality.

TREATMENT ALGORITHM

For isolated focal chondral defects of articular cartilage, success or failure of first-line treatments guides future treatment options, all of which leave options for further restoration treatments or arthroplasty (Figure 18). The location of the lesion, assuming minimal bone loss, will determine other necessary evaluations of the appropriate mechanical alignment, ligament stability, or meniscal deficiency. The size of the lesion and the degree to which it is contained, or surrounded by healthy cartilage, will further

influence treatment selections. In addition, the success or failure of first-line treatments will influence future treatment selections, as will the relative demands placed on the knee by the patient. For patellofemoral lesions, an anteromedialization tibial tubercle osteotomy is generally recommended concomitantly.

Palliative techniques, including arthroscopic lavage/debridement and in some cases marrow stimulation, are typically implemented as a first line of treatment with the intention of temporarily, if not permanently, reducing the symptoms associated with chondral lesions. Secondary procedures include reparative techniques of ACI and in some cases osteochondral grafts, which strive to restore true hyaline cartilage and are associated with greater morbidity because they usually require an open exposure. Autologous chondrocyte implantation is best used in relatively young patients with focal-contained shallow lesions. The preferable size is approximately 2 to 10 cm². Larger, deeper lesions with bone loss in an older patient may require a restorative procedure using an osteochondral implant, either autograft or allograft, depending on the lesion's size. Deficient menisci often require transplantation concomitantly with an articular cartilage procedure. Other comorbidities that require assessment and often simultaneous treatment include ligamentous instability and malalignment of the mechanical limb axis or the

patellofemoral joint. With these guidelines in mind, we have constructed a conceptual treatment algorithm based on lesion size, patient age, and success or failure of previous treatments. In this conceptual diagram, first-line treatments are selected based on lesion size and location in the context of other patient characteristics.

Concomitant Knee Abnormality

It has been well established that regardless of the technology employed, cartilage restoration procedures have better outcomes when comorbidities are corrected. This is particularly true when treating lesions in the knee, but the same principles apply to other joints in which cartilage restoration technology is used. When performing a cartilage restoration procedure, the surgeon must identify and correct a deficient meniscus, ligamentous instability, or malalignment of the mechanical limb axis or patellofemoral joint. Often, the most difficult step in correcting these associated abnormalities is identifying them. As "the eye sees only what the mind knows" (Rene Descartes, 1642), we are at risk of not properly identifying and correcting comorbid conditions unless we are looking carefully for them at the time of initial patient evaluation. Left uncorrected, comorbidities represent a relative contraindication to cartilage resurfacing. The following section will discuss the issues of meniscal transplant, ligament reconstruction, and corrective osteotomies in the setting of cartilage restoration procedures.

Meniscus Transplant. In part 1, we discussed the role the meniscus plays in protecting the articular surface through load transmission. A step-by-step technique of meniscal transplants has been described elsewhere.^{21,52,77,84,95} Attaining bone anchorage of the anterior and posterior horns is essential to providing a functional meniscus transplant. Although securing the graft with soft tissue alone is technically easier, load transmission is superior when the graft is secured with bone.^{21,91} Either bone plugs or a bone bridge in the form of a "trough," "slot," or "keyhole" is used to anchor the anterior and posterior horns. In the setting of a combined cartilage restoration and meniscal transplant, it may be necessary to use a bone plug technique, even on the lateral meniscus, to allow greater versatility and exposure of the articular cartilage. When combining cartilage restoration with a meniscal transplantation in the same compartment, it is important to plan the exact sequence of events in a detailed preoperative plan. For example, implanting an osteochondral allograft and performing a meniscal transplant to treat a deep articular cartilage defect on the lateral femoral condyle in a previously lateral meniscectomized knee will require that the posterior horn anchor be established before preparing the articular cartilage defect and implanting the osteochondral allograft plug. The bone plug and anterior horn of the meniscal allograft are gently retracted out of harm's way during implantation of the osteochondral graft and inserted in a blind tunnel at the anatomical site of the anterior horn after the osteochondral graft implantation is completed.

Corrective Osteotomies. It is commonly believed that for all of these techniques, realignment osteotomy should be performed as an adjunct procedure if the lesion is in a compartment under more than physiological compression.⁴¹

Patellofemoral joint realignment with a tibial tubercle osteotomy is a familiar procedure and has been in mainstream orthopaedics for decades.³⁰ We recommend that most cartilage restoration procedures performed on the patellofemoral joint be combined with a distal realignment procedure that anteriorizes the patella to unload the newly resurfaced patellofemoral joint. Medially based patellofemoral chondral lesions may be an exception to this generalization. Subtleties of the patellar tracking problems must be appreciated to plan the correct osteotomy. Anteriorizing the patella will unload the patellofemoral joint, whereas medializing patellar tracking may help correct lateral instability associated with a pathologic Q angle. Flatter angles will medialize more than anteriorize, and steeper angles will provide more anteriorization than medialization. There are commercially available surgical instruments to make the procedure technically easier and more precise (Tracker AMZ guide, Mitek, Norwood, Mass).

A high tibial osteotomy is required to correct the varus angulation of the lower limb mechanical axis when performing a cartilage restoration procedure in the medial compartment of a varus knee. Unlike standard high tibial osteotomy for isolated medial compartment osteoarthritis, in which the aim is to correct the mechanical axis laterally to 66% of the width of the tibial plateau in the lateral compartment,⁶⁰ high tibial osteotomies combined with cartilage restoration in the medial compartment should correct the mechanical axis to just beyond neutral. Commercially available instrumentation (Arthrex) allows for a technically simple, rapidly performed opening medial osteotomy with precision and rigid fixation. Although the opening medial osteotomy allows exposure to the medial tibia for ACL reconstruction or meniscus transplantation, there is no absolute reason to choose opening medial over closing lateral osteotomies, as long as the goals of realignment are met and the osteotomy heals without sequelae.

For valgus angulation of a knee joint with lateral compartment disease, a distal femoral osteotomy is required to restore a normal mechanical axis. As with a high tibial osteotomy to treat varus disease, the goal with a distal femoral osteotomy is to correct the mechanical axis to neutral. Care must be taken to avoid overcorrection, which creates a varus alignment. Generally, we recommend an opening lateral distal femoral osteotomy with rigid plate fixation, although other techniques and fixation methods have been described, including a percutaneous dome osteotomy combined with temporary external fixation and intramedullary nail fixation.⁴³

When performing a corrective osteotomy combined with a cartilage restoration procedure, it is critical to establish a preoperative plan that allows for a stepwise incorporation of both procedures. For example, when performing an ACI of the patellofemoral joint with a combined distal realignment, the periosteal patch must be harvested from the anteromedial tibia before making the osteotomy of the tubercle through that area. Articular cartilage lesion

preparation, graft suturing, and cell implantation require subluxation or eversion of the patella and should be performed before establishing rigid fixation of the tubercle osteotomy distally.

Ligamentous Instability. Uncorrected ligamentous instability is a contraindication to cartilage restoration procedures. Methods of ligament reconstruction are well established and will not be reviewed here. It is important to carefully plan a sequence of treatment options for each patient and to consider staging procedures if needed. If a single stage will incorporate ligament reconstruction with cartilage restoration or meniscus transplant, a preoperative plan that allows for a stepwise incorporation of both procedures is crucial. The type of concomitant procedure may affect the graft selection for ACL reconstruction. For example, when performing an ACL reconstruction in the setting of an ACI, periosteal patch harvest would occur before hamstring harvest or tibial drilling. If treating patellar defect with ACI and distal realignment, hamstring autograft or an allograft graft source would be required, as the osteotomized patellar tendon insertion would be unavailable as autograft.

If an opening medial high tibial osteotomy is required in association with an ACL reconstruction, the osteotomy can be tailored to reduce the posterior slope of the tibial plateau, which will protect the ACL reconstruction and increase anterior stability. Medialization of the tibial tunnel by rotation of the guide will limit the possibility of inadvertent communication with the osteotomy. In the setting of a high tibial osteotomy, a hamstring graft for ACL reconstruction may be considered, as it may allow for smaller tunnel diameter, thereby reducing the risk of communicating with the osteotomy. Whichever graft is selected, interference screws for tibial fixation should be used with caution, as they will create hoop stresses in the tibial tunnel aperture near the osteotomy.

If a meniscus transplant is combined with either primary or revision ACL, there are several issues to consider related to the 3-dimensional relationship of tunnels in the tibial metaphysis. Prior tunnel expansion and position, intended locations of new tunnels, ACL graft selection, and meniscus anchor method offer variability to address the needs of each particular patient. For example, the ideal entry of the ACL tunnel is at the level of the posterior edge of the anterior horn of the lateral meniscus; if performing a concomitant ACL reconstruction and lateral meniscal transplant, a slot and bone bridge technique will allow for adequate fixation even if the bone bridge is partially violated by the tibial tunnel,²¹ and a hamstring ACL graft will allow for narrower tunnels in the tibia.

If necessary, procedures should be staged and bone graft applied to metaphyseal defects. A guideline of 2 procedures per operation and staging subsequent procedures should be followed. Generally, osteotomies should be performed first, with a 6-month interval between procedures to allow for complete bone healing and remodeling. Subsequent hardware removal should be planned, and a strategy for dealing with resulting stress risers from residual empty screw holes should be devised.

FUTURE DIRECTIONS

Current research efforts are paving the way for future advances to improve results and further limit the morbidity associated with cartilage restoration. Advances in engineered matrix tissue scaffolds and bioadhesives⁴⁰ have combined with greater controlled manipulation of gene-modified tissues.³⁹ A greater understanding of the scope of pluripotential cells' differentiation and the most efficient pulse sequence of growth factor manipulation with bone morphogenic proteins⁸² will enhance our ability to process and expand tissue *ex vivo* in tissue-loading bioreactors. Advancing toward a common goal of improving the clinical outcomes of cartilage restoration will require a coordinated comprehensive approach incorporating the basic science of genetic engineering and biochemistry with outcome analyses and surgical decision making and techniques developed by clinicians.

SUMMARY

Articular cartilage damage is a problem that has posed a seemingly insurmountable challenge to the medical community for centuries. Recent advancements have allowed aggressive repair in properly selected patients, often with combined procedures. Of critical importance are issues of careful patient selection, patient counseling, and preoperative planning, especially when combined procedures are planned.

REFERENCES

1. Aglietti P, Ciardullo A, Giron F, Ponteggia F. Results of arthroscopic excision of the fragment of osteochondritis dissecans of the knee. *Arthroscopy*. 2001;17:741-746.
2. Aichroth P. Osteochondritis dissecans of the knee: a clinical survey. *J Bone Joint Surg Br*. 1971;53:440-447.
3. Anderson A. Antegrade drilling for osteochondritis dissecans. *Arthroscopy*. 1997;13:319-324.
4. Angermann P, Jensen P. Osteochondritis dissecans of the talus: long-term results of surgical treatment. *Foot Ankle*. 1989;10:161-163.
5. Baker CL, Andrews JR, Ryan JB. Arthroscopic treatment of transchondral talar dome fractures. *Arthroscopy*. 1986;2:82-87.
6. Bartz RL, Kamaric E, Noble PC, Lintner D, Bocell J. Topographic matching of selected donor and recipient sites for osteochondral autografting of the articular surface of the femoral condyles. *Am J Sports Med*. 2001;29:207-212.
7. Bauer M, Jonsson K, Linden B. Osteochondritis dissecans of the ankle: a 20-year follow-up study. *J Bone Joint Surg Br*. 1987;69:93-96.
8. Bentley G, Biant LC, Carrington RW, et al. A prospective, randomised comparison of autologous chondrocyte implantation versus mosaicplasty for osteochondral defects in the knee. *J Bone Joint Surg Br*. 2003;85:223-230.
9. Berlet GC, Mascia A, Miniaci A. Treatment of unstable osteochondritis dissecans lesions of the knee using autogenous osteochondral grafts (mosaicplasty). *Arthroscopy*. 1999;15:312-316.
10. Bert JM, Maschka K. The arthroscopic treatment of unicompartmental gonarthrosis: a five-year follow-up of abrasion arthroplasty plus arthroscopic debridement and arthroscopic debridement alone. *Arthroscopy*. 1989;5:25-32.
11. Blevins FT, Steadman JR, Rodrigo JJ, Silliman J. Treatment of articular cartilage defects in athletes: an analysis of functional outcome and lesion appearance. *Orthopedics*. 1998;21:761-768.

12. Bobic V. Arthroscopic osteochondral autograft transplantation in anterior cruciate ligament reconstruction: a preliminary clinical study. *Knee Surg Sports Traumatol Arthrosc.* 1996;3:262-264.
13. Bradley JP, Petrie RS. Osteochondritis dissecans of the humeral capitellum: diagnosis and treatment. *Clin Sports Med.* 2001;20:565-590.
14. Brittberg M, Nilsson A, Lindahl A, Ohlsson C, Peterson L. Rabbit articular cartilage defects treated with autologous cultured chondrocytes. *Clin Orthop.* 1996;326:270-283.
15. Brittberg M, Peterson L, Sjogren-Jansson E, Tallheden T, Lindahl A. Articular cartilage engineering with autologous chondrocyte transplantation: a review of recent developments. *J Bone Joint Surg Am.* 2003;85(suppl 3):109-115.
16. Bugbee WD. Fresh osteochondral allografts. *J Knee Surg.* 2002;15:191-195.
17. Bugbee WD, Convery FR. Osteochondral allograft transplantation. *Clin Sports Med.* 1999;18:67-75.
18. Byrd JW, Jones KS. Arthroscopic surgery for isolated capitellar osteochondritis dissecans in adolescent baseball players: minimum three-year follow-up. *Am J Sports Med.* 2002;30:474-478.
19. Cain EL, Clancy WG. Treatment algorithm for osteochondral injuries of the knee. *Clin Sports Med.* 2001;20:321-342.
20. Chu CR, Convery FR, Akeson WH, Meyers M, Amiel D. Articular cartilage transplantation: clinical results in the knee. *Clin Orthop.* 1999;360:159-168.
21. Cole BJ, Carter TR, Rodeo SA. Allograft meniscal transplantation: background, techniques, and results. *Instr Course Lect.* 2003;52:383-396.
22. Cole BJ, Fox J, Nho S, et al. Prospective evaluation of autologous chondrocyte implantation. Paper presented at: Annual Meeting of the American Academy of Orthopaedic Surgeons; February 2003; New Orleans, La.
23. Cugat R, Garcia M, Cusco X, et al. Osteochondritis dissecans: a historical review and its treatment with cannulated screws. *Arthroscopy.* 1993;9:675-684.
24. D'Amato M, Cole BJ. Autologous chondrocyte implantation. *Orthop Tech.* 2001;11:115-131.
25. Duchow J, Hess T, Kohn D. Primary stability of press-fit-implanted osteochondral grafts: influence of graft size, repeated insertion, and harvesting technique. *Am J Sports Med.* 2000;28:24-27.
26. Ergelet C, Sittinger M, Lahm A. The arthroscopic implantation of autologous chondrocytes for the treatment of full-thickness cartilage defects of the knee joint. *Arthroscopy.* 2003;19:108-110.
27. Fowler JL, Wicks MH. Osteochondritis dissecans of the lunate. *J Hand Surg Am.* 1990;15:571-572.
28. Freedman KB, Nho SJ, Cole BJ. Marrow stimulating technique to augment meniscus repair. *Arthroscopy.* 2003;19:794-798.
29. Frisbie DD, Trotter GW, Steadman JR. Arthroscopic subchondral bone plate microfracture technique augments healing of large chondral defects in the radial carpal bone and medial femoral condyle of horses. *Vet Surg.* 1999;28:242-255.
30. Fulkerson JP. Anteromedialization of the tibial tuberosity for patellofemoral malalignment. *Clin Orthop.* 1983;177:176-178.
31. Garretson RB III, Katolik LI, Verma N, Beck BR, Cole BJ. Contact pressure at osteochondral donor sites in the patellofemoral joint. *Am J Sports Med.* 2004;32:967-974.
32. Garrett JC. Osteochondral allografts for reconstruction of articular defects of the knee. *Instr Course Lect.* 1998;47:17-522.
33. Ghazavi MT, Pritzker KP, Davis AM, Gross AE. Fresh osteochondral allografts for post-traumatic osteochondral defects of the knee. *J Bone Joint Surg Br.* 1997;79:1008-1013.
34. Giannini S, Buda R, Grigolo B, Vannini F. Autologous chondrocyte transplantation in osteochondral lesions of the ankle joint. *Foot Ankle Int.* 2001;22:513-517.
35. Gill T. The role of the microfracture technique in the treatment of full-thickness chondral injuries. *Oper Tech Sports Med.* 2000;8:138-140.
36. Gill T, Macgillivray J. The technique of microfracture for the treatment of articular cartilage defects in the knee. *Oper Tech Orthop.* 2001;2:105-107.
37. Gillogly SD, Voight M, Blackburn T. Treatment of articular cartilage defects of the knee with autologous chondrocyte implantation. *J Orthop Sports Phys Ther.* 1998;28:241-251.
38. Gobbi A, Nunag P, Malinowski K. Treatment of full thickness chondral lesions of the knee with microfracture in a group of athletes. *Knee Surg Sports Traumatol Arthrosc.* In press.
39. Grande D, Breidbart A, Mason J, Paulino C, Laser J, Schwartz R. Cartilage tissue engineering: current limitations and solutions. *Clin Orthop.* 1999;367(suppl):S176-S185.
40. Grande D, Halberstadt C, Naughton G, Schwartz R. Evaluation of matrix scaffolds for tissue engineering of articular cartilage grafts. *J Biomed Mater Res.* 1997;34:211-220.
41. Gross AE. Fresh osteochondral allografts for post-traumatic knee defects: surgical technique. *Oper Tech Orthop.* 1997;7:334-339.
42. Gross AE. Repair of cartilage defects in the knee. *J Knee Surg.* 2002;15:167-169.
43. Gugenheim JJ Jr, Brinker MR. Bone realignment with use of temporary external fixation for distal femoral valgus and varus deformities. *J Bone Joint Surg Am.* 2003;85:1229-1237.
44. Hangody L, Feczko P, Bartha L, Bado G, Kish G. Mosaicplasty for the treatment of articular defects of the knee and ankle. *Clin Orthop.* 2001;391(suppl):S328-S336.
45. Hangody L, Füles P. Autologous osteochondral mosaicplasty for the treatment of full-thickness defects of weight-bearing joints: ten years of experimental and clinical experience. *J Bone Joint Surg Am.* 2003;85(suppl 2):25-32.
46. Hangody L, Kish G, Karpati Z, et al. Osteochondral plugs: autogenous osteochondral mosaicplasty for the treatment of focal chondral and osteochondral articular defects. *Oper Tech Orthop.* 1997;7:312-322.
47. Hangody L, Kish G, Modis L, et al. Mosaicplasty for the treatment of osteochondritis dissecans of the talus: two to seven year results in 36 patients. *Foot Ankle Int.* 2001;22:552-558.
48. Harada M, Ogino T, Takahara M, Ishigaki D, Kashiwa H, Kanauchi Y. Fragment fixation with a bone graft and dynamic staples for osteochondritis dissecans of the humeral capitellum. *J Shoulder Elbow Surg.* 2002;11:368-372.
49. Horas U, Pelinkovic D, Herr G, Aigner T, Schnettler R. Autologous chondrocyte implantation and osteochondral cylinder transplantation in cartilage repair of the knee joint: a prospective, comparative trial. *J Bone Joint Surg Am.* 2003;85:185-192.
50. Hunziker EB, Quinn TM. Surgical removal of articular cartilage leads to loss of chondrocytes from cartilage bordering the wound edge. *J Bone Joint Surg Am.* 2003;85(suppl 2):85-92.
51. Johansen O, Lindahl A, Peterson L, et al. Hip osteochondritis treated by debridement, suture of a periosteal flap and chondrocyte implantation: a case report. In: Hunziker E, Mainil-Varlet P, eds. *Updates in Cartilage Repair: A Multimedia Production on Cartilage Repair* [6 CD-ROMs]. Philadelphia, Pa: Lippincott Williams and Wilkins; 2000.
52. Johnson DL, Swenson TM, Livesay GA, Aizawa H, Fu FH, Harner CD. Insertion-site anatomy of the human menisci: gross, arthroscopic, and topographical anatomy as a basis for meniscal transplantation. *Arthroscopy.* 1995;11:386-394.
53. Jurgenson I, Bachmann G, Haas H, et al. Effect of arthroscopic therapy on osteochondritis dissecans of the knee and ankle. *Arthroscopie.* 1998;11:193-199.
54. Kivisto R, Pasanen L, Leppilahti J. Arthroscopic repair of osteochondritis dissecans of the femoral condyles with metal staple fixation: a report of 28 cases. *Knee Surg Sports Traumatol Arthrosc.* 2002;10:305-309.
55. Knutsen G, Engebretsen L, Ludvigsen TC, et al. Autologous chondrocyte implantation compared with microfracture in the knee: a randomized trial. *J Bone Joint Surg Am.* 2004;86:455-464.
56. Koullalis D, Schultz W. Massive intraosseous ganglion of the talus: reconstruction of the articular surface of the ankle joint. *Arthroscopy.* 2000;16:E14.
57. Koullalis D, Schultz W, Heyden M. Autologous chondrocyte transplantation for osteochondritis dissecans of the talus. *Clin Orthop.* 2002;395:186-192.

58. Krijnen MR, Lim L, Willems WJ. Arthroscopic treatment of osteochondritis dissecans of the capitellum: report of 5 female athletes. *Arthroscopy*. 2003;19:210-214.
59. Lee CR, Grodzinsky AJ, Hsu HP, Spector M. Effects of a cultured autologous chondrocyte-seeded type II collagen scaffold on the healing of a chondral defect in a canine model. *J Orthop Res*. 2003;21:272-281.
60. Lobenhoffer P, Agneskirchner JD. Improvements in surgical technique of valgus high tibial osteotomy. *Knee Surg Sports Traumatol Arthrosc*. 2003;11:132-138.
61. Mandelbaum BR, Gerhardt MB, Peterson L. Autologous chondrocyte implantation of the talus. *Arthroscopy*. 2003;19(suppl 1):129-137.
62. McDermott AG, Langer F, Pritzker KP, Gross AE. Fresh small-fragment osteochondral allografts: long-term follow-up on the first 100 cases. *Clin Orthop*. 1985;197:96-102.
63. Micheli LJ, Browne JE, Ergelet C, et al. Autologous chondrocyte implantation of the knee: multicenter experience and minimum 3-year follow-up. *Clin J Sport Med*. 2001;11:223-228.
64. Minas T. Autologous chondrocyte implantation for focal chondral defects of the knee. *Clin Orthop*. 2001;391(suppl):S349-S361.
65. Minas T, Chiu R. Autologous chondrocyte implantation. *Am J Knee Surg*. 2000;13:41-50.
66. Minas T, Peterson L. Advanced techniques in autologous chondrocyte transplantation. *Clin Sports Med*. 1999;18:13-44.
67. Mitsunaga M, Adishian DA, Bianco AJ Jr. Osteochondritis dissecans of the capitellum. *J Trauma*. 1982;22:53-55.
68. Navarro R, Cohen M, Filho MC. The arthroscopic treatment of osteochondritis dissecans of the knee with autologous bone sticks. *Arthroscopy*. 2002;18:840-844.
69. Newman AP. Articular cartilage repair. *Am J Sports Med*. 1998;26:309-324.
70. Nilsson A, Lindahl A, Peterson L, et al. Autologous chondrocyte transplantation of the human wrist. In: Hunziker E, Mainil-Varlet P, eds. *Updates in Cartilage Repair: A Multimedia Production on Cartilage Repair* [6 CD-ROMs]. Philadelphia, Pa: Lippincott Williams and Wilkins; 2000.
71. Pappas AM. Osteochondritis dissecans. *Clin Orthop*. 1981;158:59-69.
72. Pearce SG, Hurtig MB, Clarnette R, Kalra M, Cowan B, Miniaci A. An investigation of 2 techniques for optimizing joint surface congruency using multiple cylindrical osteochondral autografts. *Arthroscopy*. 2001;17:50-55.
73. Peterson L, Brittberg M, Kiviranta I, Akerlund EL, Lindahl A. Autologous chondrocyte transplantation: biomechanics and long-term durability. *Am J Sports Med*. 2002;30:2-12.
74. Peterson L, Menche D, Grande D, et al. Chondrocyte transplantation: an experimental model in the rabbit. *Trans Orthop Res Soc*. 1984;9:218.
75. Peterson L, Minas T, Brittberg M, Nilsson A, Sjogren-Jansson E, Lindahl A. Two- to 9-year outcome after autologous chondrocyte transplantation of the knee. *Clin Orthop*. 2000;374:212-234.
76. Pill SG, Ganley TJ, Flynn JM, Gregg JR. Osteochondritis dissecans of the capitellum: arthroscopic-assisted treatment of large, full-thickness defects in young patients. *Arthroscopy*. 2003;19:222-225.
77. Rodeo SA. Meniscal allografts: where do we stand? *Am J Sports Med*. 2001;29:246-261.
78. Romeo AA, Cole BJ, Mazzocca AD, Fox JA, Freeman KB, Joy E. Autologous chondrocyte repair of an articular defect in the humeral head. *Arthroscopy*. 2002;18:925-929.
79. Schenk RC, Goodnight JM. Current concepts review: osteochondritis dissecans. *J Bone Joint Surg Am*. 1996;78:439-456.
80. Schwarz C, Blazina ME, Sisto DJ, Hirsh LC. The results of operative treatment of osteochondritis dissecans of the patella. *Am J Sports Med*. 1988;16:522-528.
81. Sekiya LC, Fontbote CA, Harner CD. Arthroscopically assisted retrograde fixation of patellar osteochondritis dissecans using fluoroscopic guidance: a case report and technical note. *Arthroscopy*. 2003;19:E1-E7.
82. Sellers R, Zhang R, Glasson SS, et al. Repair of articular cartilage defects one year after treatment with recombinant human bone morphogenetic protein-2 (rhBMP-2). *J Bone Joint Surg Am*. 2000;82:151-160.
83. Sgaglione NA, Miniaci A, Gillogly SD, Carter TR. Update on advanced surgical techniques in the treatment of traumatic focal articular cartilage lesions in the knee. *Arthroscopy*. 2002;18(suppl 1):9-32.
84. Shelton WR, Dukes AD. Meniscus replacement with bone anchors: a surgical technique. *Arthroscopy*. 1994;10:324-327.
85. Shwarz C, Blazina ME, Sisto DJ, Hirsch LC. The results of operative treatment of osteochondritis dissecans of the patella. *Am J Sports Med*. 1988;16:522-529.
86. Simonian PT, Sussmann PS, Wickiewicz T, Paletta GA, Warren RF. Contact pressures at osteochondral donor sites in the knee. *Am J Sports Med*. 1998;26:491-494.
87. Slough J, Noto A, Schmidt T. Tibial cortical bone peg fixation in OCD of the knee. *Clin Orthop*. 1991;267:122-127.
88. Steadman JR, Briggs KK, Rodrigo JJ, Kocher MS, Gill TJ, Rodkey WG. Outcomes of microfracture for traumatic chondral defects of the knee: average 11-year follow-up. *Arthroscopy*. 2003;19:477-484.
89. Steadman JR, Rodkey WG, Rodrigo JJ. Microfracture: surgical technique and rehabilitation to treat chondral defects. *Clin Orthop*. 2001;391(suppl):S362-S369.
90. Steadman JR, Rodkey WG, Singelton SB, et al. Microfracture technique for full thickness chondral defects: technique and clinical results. *Oper Tech Orthop*. 1997;7:300-307.
91. Szomor ZL, Martin TE, Bonar F, Murrell GA. The protective effects of meniscal transplantation on cartilage: an experimental study in sheep. *J Bone Joint Surg Am*. 2000;82:80-88.
92. Thomson N. Osteochondritis dissecans and osteochondral fragments managed by Herbert compression screw fixation. *Clin Orthop*. 1987;224:71-78.
93. Verhagen RA, Struijs PA, Bossuyt PM, van Dijk CN. Systematic review of treatment strategies for osteochondral defects of the talar dome. *Foot Ankle Clin*. 2003;8:233-242, viii-ix.
94. Weiler A, Hoffmann RF, Stahelin AC, Helling HJ, Sudkamp NP. Biodegradable implants in sports medicine: the biological base. *Arthroscopy*. 2000;16:305-321.
95. Wilcox TR, Goble EM, Doucette SA. Goble technique of meniscus transplantation. *Am J Knee Surg*. 1996;9:37-42.
96. Wouters DB, van Horn JR, Bos RR. The use of biodegradables in the treatment of osteochondritis dissecans of the knee: fiction or future? *Acta Orthop Belg*. 2003;69:175-181.
97. Zuniga JJR, Sagastibelza J, Lopez Blasco JJ, Martinez Grande M. Arthroscopic use of the Herbert screw in osteochondritis dissecans of the knee. *Arthroscopy*. 1993;9:668-670.