

## Case Report

# Rapid Progression of Chondral Disease in the Lateral Compartment of the Knee Following Meniscectomy

J. Winslow Alford, M.D., Paul Lewis, B.S., Richard W. Kang, B.S.,  
and Brian J. Cole, M.D., M.B.A.

---

**Abstract:** We present 2 cases of severe, rapidly progressive chondral disease in the lateral compartment within 12 months after meniscectomy. In both cases, the lateral compartment was salvaged with simultaneously performed cartilage repair techniques and meniscal transplantation. The first case is of a 16-year-old boy who suffered a complex irreparable posterior horn lateral meniscus tear that was treated with an aggressive partial meniscectomy, and developed a rapid onset of severe lateral compartment symptoms associated with a focal grade IV chondral defect of the lateral femoral condyle within 10 months of his index meniscectomy. The second case is that of an athletic 43-year-old orthopaedic surgeon who suffered a complex lateral meniscus tear that required a near total lateral meniscectomy. Within 5 months of the lateral meniscectomy, he developed severe lateral symptoms with a focal grade IV chondral defect of the lateral femoral condyle. In both cases, the articular cartilage defects were treated with osteochondral grafting at the time of lateral meniscus transplantation with excellent results at 2-year follow-up. These cases highlight the significant need for a heightened awareness of the relatively increased risk of rapid lateral compartment degeneration following lateral meniscectomy. This, in combination with the appropriate use of cartilage restoration techniques, provides the potential to salvage or prevent rapid onset, unicompartmental degenerative disease, and the ability to reduce symptoms and improve function in these challenging patients. **Key Words:** Lateral compartment—Knee—Meniscectomy—Degenerative joint disease.

---

**I**t is well established that the altered biomechanics in the partially and completely meniscectomized knee lead to a progression of degenerative changes.<sup>1,2</sup> After meniscectomy, in the lateral compartment, unique anatomic and biomechanical factors lead to a relatively higher risk of tibiofemoral articular degeneration when compared with the medial compartment.<sup>3</sup> In the

appropriate clinical setting, this predictable progression of cartilage degeneration may be attenuated and even avoided by early intervention and combined treatment of localized articular cartilage degeneration and the meniscectomized state. Meniscal allograft transplantation, osteochondral grafting (allograft or autograft), autologous chondrocyte implantation, and realignment osteotomies are some of the treatment alternatives used to restore the lateral compartment once these patients develop symptoms (e.g., ipsilateral pain, swelling, and progressive loss of function).<sup>3,4</sup> Although not all patients will do poorly after lateral meniscectomy, it is our experience that once these patients become symptomatic, they have a propensity to rapidly deteriorate over a relatively short period of time.

We present 2 cases of severe, rapid progression of

---

*From the Sports Medicine Division, Department of Orthopedics (J.W.A., B.J.C.), the Cartilage Restoration Center (P.L., R.W.K.); and Department of Anatomy and Cell Biology (B.J.C., R.W.K.), Rush University, Chicago, Illinois, U.S.A.*

*Address correspondence and reprint requests to Brian J. Cole, M.D., M.B.A., 1725 West Harrison St, Suite 1063, Chicago, IL 60612, U.S.A. E-mail: bcole@rushortho.com*

*© 2005 by the Arthroscopy Association of North America*

*0749-8063/05/2112-05-80\$30.00/0*

*doi:10.1016/j.arthro.2005.03.036*

chondral disease in the lateral compartment within 12 months of meniscectomy in which the lateral compartments were salvaged with simultaneously performed cartilage repair techniques and meniscal transplantation. The significance of these cases is the need for a heightened awareness of the relatively increased risk of rapid lateral compartment degeneration following lateral meniscectomy. Early treatment of this progression is recommended because delayed treatment may otherwise be complicated by the development of bipolar tibiofemoral degeneration.<sup>5</sup>

### CASE 1

S. R. is a healthy, athletic 16-year-old boy who suffered a noncontact twisting injury to his left knee while playing soccer. He had no history of knee problems and his mechanical axis alignment was in slight symmetric physiologic varus. He presented with localized lateral joint tenderness and complaints of pain with rotation, compression, and valgus stress. The examination was otherwise unremarkable. Preoperative magnetic resonance imaging (MRI) was consistent with a complex lateral meniscus tear (Fig 1A). At his index surgery 2 months after his injury, he underwent a subtotal lateral meniscectomy for an irreparable lateral meniscus tear. The tibiofemoral articular surfaces were found to be in pristine condition.

His immediate postoperative course was unremarkable. At 3 months, he attempted a gradual return to sports but experienced activity-related swelling and worsening lateral compartment pain. There was no specific second traumatic incident; because of worsening symptoms, a second MRI was obtained that revealed a focal chondral lesion of the lateral femoral condyle. At this time, he was referred to our practice for evaluation and treatment.

On physical examination 7 months after the index surgery, his left knee was tender on the lateral joint line and over the lateral femoral condyle. There was a mild effusion and pain with compression, rotation, and valgus stress. Quadriceps atrophy was present (2 cm less thigh circumference than the uninjured thigh). Ligamentous testing was unremarkable. He reported no tenderness on the medial joint line. He was in 4° of symmetric bilateral mechanical axis varus and ambulated without a limp or varus thrust. Plain radiographs had no evidence of fracture or chronic degenerative changes, but did show wide open physes. A repeat MRI obtained 7 months after his meniscectomy revealed increased edema in the subchondral bone of the tibia and the femoral condyle. Because of the patient's

skeletal immaturity, a lateral unloader brace was prescribed in an attempt to delay surgical intervention and thus allow further closure of the growth plates.

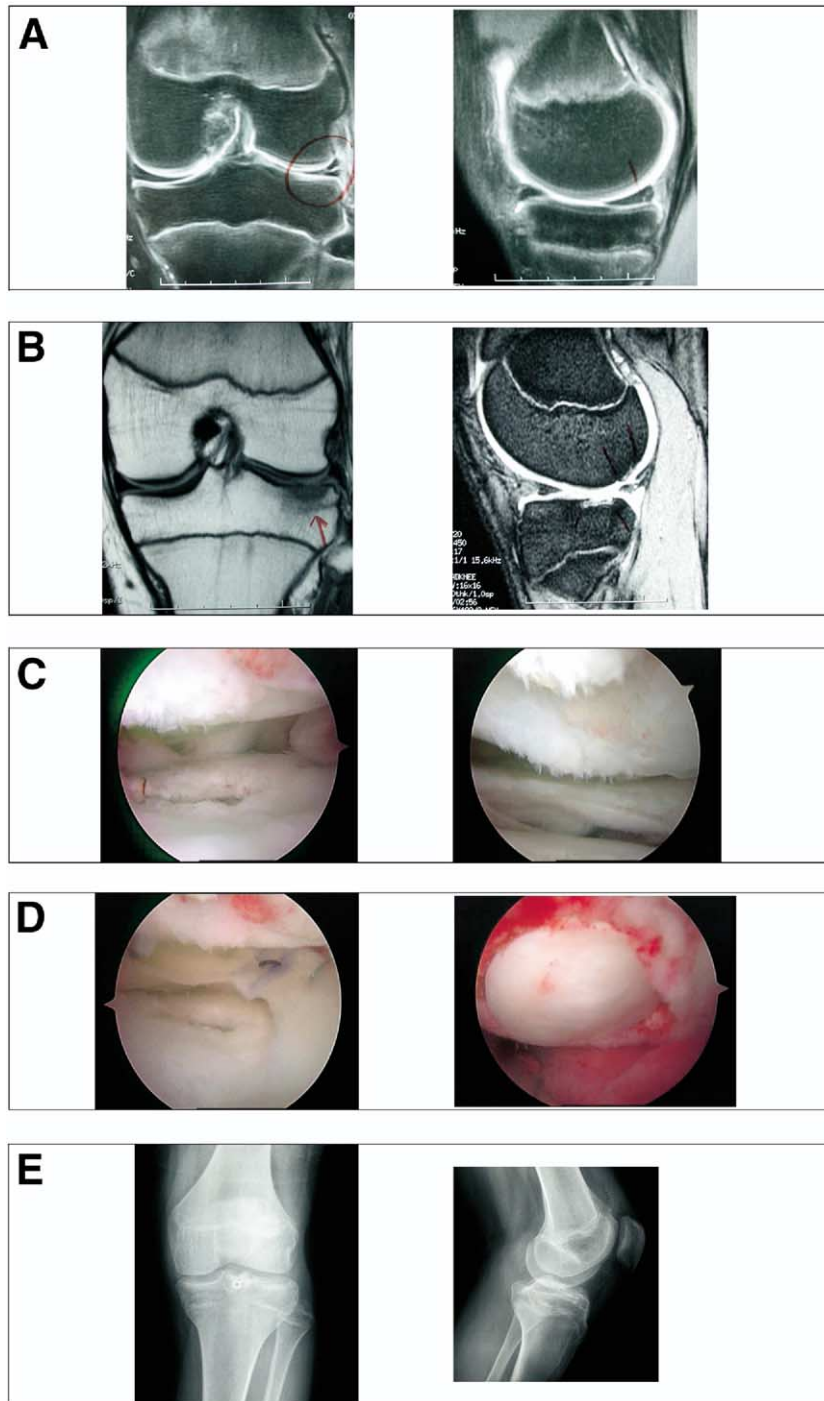
The patient was prescribed "relative rest" (i.e., closed-chain, straight-line conditioning with no cutting or competitive play) and an MRI was reordered to check for progression. The MRI taken 9 months after his index meniscectomy showed increasing edema in the subchondral bone of the lateral tibial plateau and a grade IV lateral femoral condyle lesion (Fig 1B). In an effort to halt or curtail the rapid progression of chondral disease, a decision was made with the patient and his family to proceed with surgical intervention.

Ten months after the index meniscectomy and the failure of conservative treatment, and with radiographic evidence of disease progression, the patient underwent diagnostic arthroscopy that confirmed grade IV kissing lesions on the posterior femoral condyle measuring 10 × 12 mm and the corresponding articulation of the tibial plateau with a grade IV lesion measuring 5 × 5 mm (Fig 1C). After microfracture of the smaller tibia lesion, a lateral meniscus transplant was performed using the bridge in slot technique with interference screw fixation (Fig 1D),<sup>6-8</sup> in addition to a 10-mm osteochondral autograft transplant of the lateral femoral condyle (Fig 1D).

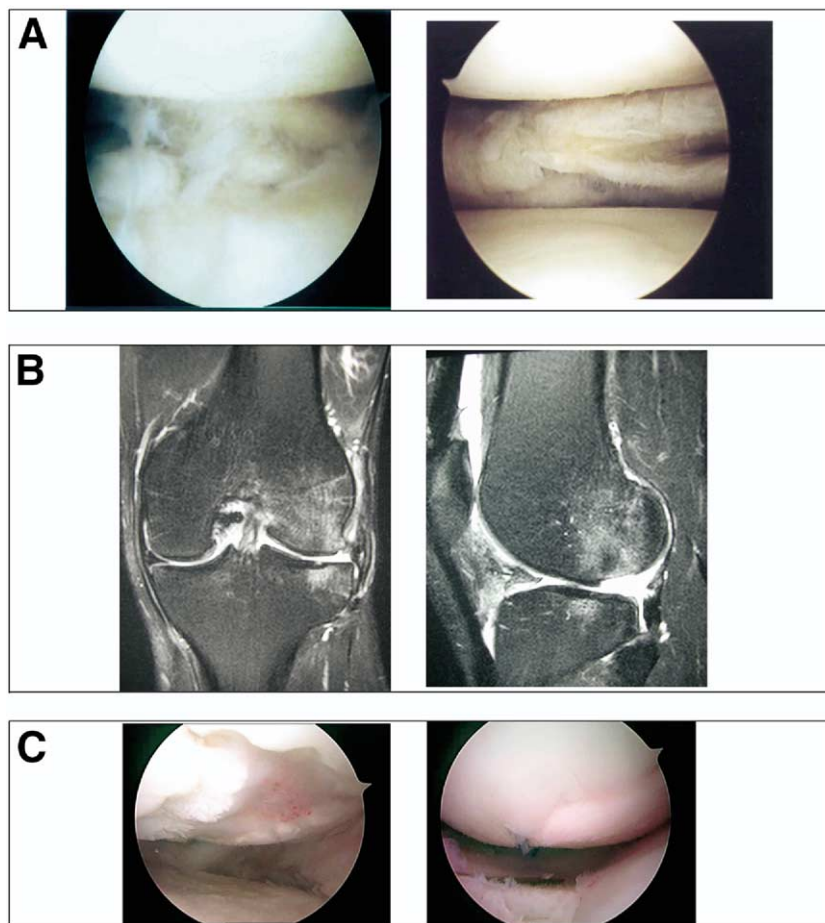
For the first 2 weeks, he remained completely non-weight bearing; the hinged knee brace remained locked in extension and was removed only for hygiene, supervised physical therapy, and continuous passive motion. At 6 weeks, he reported minimal pain and progressed to walking with 1 crutch. Full weight bearing without a limp was achieved at 12 weeks when a program emphasizing active strengthening and proprioceptive activities was begun. At 16 months after surgery, the patient was pain free and engaged in running and agility drills with high-impact activities. At 24 months, radiographs showed complete integration of the allograft and chondral plug (Fig 1E), and his symptoms resolved.

### CASE 2

J. J. is a 43-year-old orthopaedic surgeon and avid runner in good health who presented with a 6-month history of left knee lateral joint line pain, clicking, and swelling with activity. Initially this was managed with activity modification and a slow return to jogging. However, even this controlled activity caused swelling and was painful, especially when associated with incidental knee rotation. Two cortisone injections provided a brief period of relief from his symptoms.



**FIGURE 1.** Case 1 imaging and arthroscopy. (A) Preoperative MRI: (left) coronal and (right) sagittal T2-weighted images showing a complex posterior horn lateral meniscus tear. (B) MRI 9 months after index meniscectomy: (left) coronal T1-weighted and (right) sagittal T2-weighted images showing increased edema in subchondral bone of the left lateral tibial plateau and a focal chondral defect of the lateral femoral condyle. (C) Diagnostic arthroscopy showing (left) focal tibial condyle lesion, subtotal lateral meniscectomy, and femoral condyle lesion, and (right) a lateral femoral condyle lesion. (D) Definitive treatment: (left) lateral meniscus transplant in place and (right) osteochondral autograft plug in the lateral femoral condyle. (E) (Left) anteroposterior and (right) lateral radiographs 24 months postoperatively showing graft integration and proper interference screw position adjacent to meniscus bone bridge with no evidence of joint space narrowing.



**FIGURE 2.** Case 2 imaging and arthroscopy. (A) Index and revision arthroscopy: (left) index arthroscopy showing complex irreparable lateral meniscus tear with normal articular surfaces and (right) arthroscopy performed several weeks later because of recurrent symptoms leading to further removal of unstable flaps of the lateral meniscus, also with normal articular surfaces. (B) MRI 5 months after index meniscectomy: (left) coronal T-1 weighted MRI shows absence of lateral meniscus and subchondral edema on femur and tibia with early osteophyte formation of the lateral femoral condyle and (right) sagittal T-1 weighted image shows focal loss of articular cartilage on posterior aspect of the lateral femoral condyle. (C) Diagnostic and treatment arthroscopy: (left) diagnostic arthroscopy at 5 months revealed absence of lateral meniscus and a focal chondral lesion of the weight-bearing portion of the lateral femoral condyle, and (right) after lateral meniscal and fresh osteochondral allograft transplantation.

Arthroscopic evaluation of his left knee revealed a complex horizontal tear with several flaps at the popliteal tendon extending into the junction of the middle and anterior horn (Fig 2A). At the time of this arthroscopy, the articular surfaces were pristine and no other pathologies were found. A subtotal lateral meniscectomy was performed. Several weeks later, his symptoms remained unchanged and a second arthroscopic meniscectomy was performed to remove residual unstable torn lateral meniscal tissue. There was no evidence of articular cartilage degeneration (Fig 2A).

Postoperatively, his activity levels increased and included jogging. With these and lesser activities, however, the patient developed lateral-sided knee pain

and swelling. A postoperative MRI performed 5 months after the index lateral meniscectomy revealed advanced degenerative changes in the left lateral femoral condyle with significant cartilage loss over the posterior two thirds of the lateral femoral condyle. The defect was estimated to be approximately  $20 \times 20$  mm with a reciprocating tibial defect measuring less than 3 mm in diameter (Fig 2B).

With these findings of rapid and progressive chondral disease and appropriate symptoms, the patient was referred to our practice for evaluation. On examination, he had a mild effusion, full range of motion, tender lateral joint line, equivocal lateral flexion McMurray's sign, and normal mechanical axis of his left

leg. He initially underwent a diagnostic arthroscopy to help determine the appropriate treatment option (i.e., autologous chondrocyte implantation or fresh osteochondral allograft transplantation). This arthroscopy 5 months after the index lateral meniscectomy revealed a nearly absent lateral meniscus except for a small amount of intact anterior horn. There was thinning of the articular cartilage on the lateral tibial plateau with diffuse grade II changes. There was a focal grade IV defect on the posterocentral aspect of the lateral femoral condyle that measured  $24 \times 24$  mm (Fig 2C).

Because of the findings of early degenerative arthritis of the tibia combined with the patient's desire to rapidly return to work following definitive treatment, the patient was indicated for a fresh osteochondral allograft transplant of the lateral femoral condyle with simultaneous lateral meniscal transplant. Seven months after his index surgery, these procedures were performed via a lateral parapatellar arthrotomy using a single  $25 \times 25 \times 8$  mm fresh osteochondral allograft using a technique previously described,<sup>9</sup> and a lateral meniscus allograft transplant inserted using the bridge in slot technique (Fig 2C). The patient was made non-weight bearing for 8 weeks postoperatively and he used continuous passive motion for the first 6 weeks. He advanced uneventfully through a rehabilitation protocol similar to the first case presented and he returned to all activities including skiing and running 16 months postoperatively. Three years following his combined transplant, he remains pain free with full range of motion.

## DISCUSSION

The sequelae after removal of significant portions of the lateral meniscus have been recognized for decades<sup>1</sup> and are largely due to the unique anatomy and biomechanics of the lateral compartment. These 2 cases we present not only support this, but also highlight the need for clinicians to identify patients with a lateral meniscectomized knee as a high-risk population for potentially rapid progression of chondral disease. Allograft meniscus transplantation, osteochondral allograft and autograft transplantation, and autologous chondrocyte implantation are all considered potential treatment options for patients with com-

bined meniscal deficiency and high-grade ipsilateral chondral disease.

In our cases, the coexisting articular cartilage disease, which would otherwise be considered a relative contraindication to allograft meniscus transplantation, was treated with osteochondral grafting (autograft in Case 1 and fresh allograft in Case 2). The rationale for treating the defect simultaneously with meniscus allograft transplantation has been described previously.<sup>10</sup> By doing so we were able to eliminate the factors known to be detrimental for meniscus transplantation and allow for better long-term results. Likewise, a meniscus transplant has been shown to offer mechanical protection to the articular cartilage surface.<sup>11</sup> In our cases, there were no valgus deformities that would otherwise place undue strain on the lateral compartment and require correction. Finally, the importance of meticulous patient compliance with postoperative protocols cannot be overstated.

## REFERENCES

1. Fairbanks TJ. Knee joint changes after meniscectomy. *J Bone Joint Surg Br* 1948;30:664-670.
2. Tapper EM, Hoover NW. Late results after meniscectomy. *J Bone Joint Surg Am* 1969;51:517-526.
3. Paletta GA Jr, Manning T, Snell E, et al. The effect of allograft meniscal replacement on intraarticular contact area and pressures in the human knee. A biomechanical study. *Am J Sports Med* 1997;25:692-698.
4. Cole BJ, Carter TR, Rodeo SA. Allograft meniscal transplantation: Background, techniques, and results. *Instr Course Lect* 2003;52:383-396.
5. Ahmed AM, Burke DL. In-vitro measurement of static pressure distribution in synovial joints—Part I: Tibial surface of the knee. *J Biomech Eng* 1983;105:216-225.
6. Farr J, Meneghini RM, Cole BJ. Allograft interference screw fixation in meniscus transplantation. *Arthroscopy* 2004;20:322-327.
7. Cole BJ, Fox JA, Lee SJ, Farr J. Bone bridge in slot technique for meniscal transplantation. *Oper Tech Sports Med* 2003;11:144-155, 2003.
8. Fox JA, Lee SJ, Cole BJ. Bone plug technique for meniscal transplantation. *Oper Tech Sports Med* 2003;11:161-169, 2003.
9. Fox JA, Freedman KB, Lee SJ, Cole BJ. Fresh osteochondral allograft transplantation for articular cartilage defects. *Oper Tech Sports Med* 2002;10:168-173.
10. Cole BJ, DiMasi M. Single-stage autologous chondrocyte implantation and lateral meniscus allograft reconstruction. *Orthop Tech Rev* 2000;2:44-59.
11. Szomor ZL, Martin TE, Bonar F, Murrell GA. The protective effects of meniscal transplantation on cartilage. An experimental study in sheep. *J Bone Joint Surg Am* 2000;82:80-88.